

Directions: Questions (1-32) Circle the one best answer

- D** 1. A 44-year-old white man presents with the history of exertional dyspnea with minimal activity of few weeks duration. He is known to have a idiopathic congestive cardiomyopathy for the last one year. His medications include digoxin, furosemide, lisinopril, carvediol, and spiranolactone. The EKG reveals a LBBB pattern with a QRS duration of 140 ms. The Echocardiogram reveals marked left ventricular enlargement, severely decreased systolic function with a LVEF of 22%. Based upon the above information, you will now recommend:
(A) Add hydralazine and isosrbide
(B) Biventricular pacemaker
(C) ICD insertion
(D) Biventricular pacemaker and ICD insertion
- D** 2. A 50-year-old man is seen for an annual examination. He denies any chest pain, dyspnea or palpitations. The physical examination reveals a presence of S3 and a midsystolic click followed by a systolic murmur. The murmur radiates to the axilla and becomes louder and longer on standing. The echocardiogram reveals severe mitral regurgitation and a prolapse of the posterior mitral valve leaflet. The left ventricular end-systolic diameter is 52 mm with a ejection fraction of 46 % Based upon the above information you will now recommend:
(A) Repeat an echocardiogram in one year
(B) Start lisinoprl
(C) Start amlodipine
(D) Mitral valve surgery
- A** 3. A 40-year-old aympntomatic woman is seen for a routine physical examination. The examination reveals a pulse of 80/minute, BP 150/60 and there is no jugular venous distension. There are brisk, prominent distal pulses throughout the extremities with a "pistol shot sound heard when ascultating over the peripheral arteries. There is an early decrescendo diastolic murmur heard over the left lower sternal border. The echocardiogram reveals severe aortic regurgitation . The left ventricular systolic diameter is 60 mm and left ventricular ejection fraction is 40%. Based upon the above information, you will now recommend:
(A) Aortic valve replacement
(B) Atenolol
(C) Nifedipine
(D) Repeat echocardiogram in one year.
- C** 4. A 16-year old male has a 4/6 holosystolic murmur over left lower sternal border. The murmur does not change with respiration and increases with hand grip exercises. The most likely diagnosis is:
(A) Mitral regurgitation
(B) Tricuspid regurgitation
(C) Ventricular septal defect

C 5. A 45-year-old male presents with sudden onset of left hemiparesis. He also gives a history of low grade fever, weight loss, exertional dyspnea and few episodes of sudden syncope for the last few weeks. The physical examination reveals a temperature of 99.8 F, BP 130/80 and the weakness of left arm and leg. The cardiac examination reveals a loud P2, low-pitched early diastolic sound and a apical systolic murmur which changes in intensity with changes of position of the body. The laboratory studies show an Hb 9 g/dL, Hct 28% and a sedimentation of 90 mm/h. based upon the above information, the most likely diagnosis is:

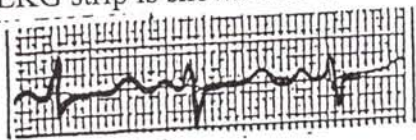
→ atrial myxoma

- (A) Mitral stenosis
- (B) Bacterial endocarditis
- (C) Atrial myxoma
- (D) Paradoxical emboli secondary to patent foramen ovale

D 6. A 20-year-old male patient who is a member of the basketball team of his college comes for routine examination. He denies any dyspnea or syncope. The physical examination reveals a heart rate of 50/minute, BP 110/70, soft S3 and a grade 1 ejection systolic murmur over left sternal border. The murmur decreases in intensity with standing and valsalva's maneuver and increases after exercise. The EKG reveals mild left ventricular hypertrophy, sinus bradycardia, and sinus arrhythmia and sinus arrest with pauses up to 1 second. The echocardiogram reveals no valvular abnormality, LVEF 64% and the septal and posterior wall thickness of 12 mm. Based upon the above information you will now recommend:

- (A) Advise him not to participate in any competitive sports
- (B) Start treatment with B blockers
- (C) Advise a permanent pacemaker
- (D) No therapy is required at this time

C 7. A 16-year-old female presents with recurrent loss of consciousness and most recent attack occurred when she was awakened by an alarm clock. The physical examination reveals a pulse of 60/minute, BP 120/80, no focal neurological findings and the cardiac examination reveals normal heart sounds and no murmurs. The EKG strip is shown below



Based upon the above information, the most important question to ask her:

- (A) History of cocaine use
- (B) History of alcohol abuse
- (C) History of sudden death in the family
- (D) Family history of seizures

C 8.

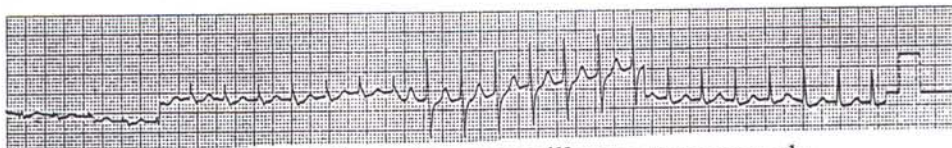
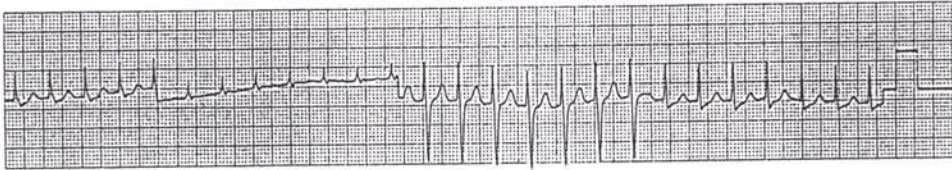
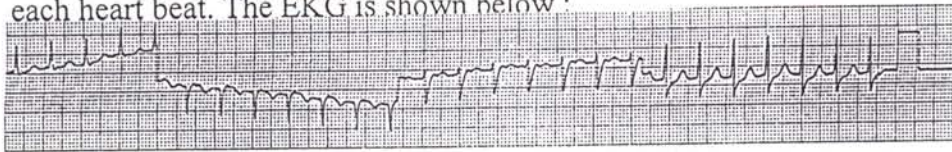
A 64-year-old patient consults you because of one-month history of exertional chest pain and two episodes of syncope after exertion in the last 2 weeks. The physical examination reveals pulse 80/minute with slow carotid upstroke, BP 120/80, CVS: S4 +, grade 3/6 ejection systolic murmur over LSB and aortic area. The murmur radiates to the carotids and decreases in intensity on standing. The echocardiogram reveals a 40 mm gradient across the aortic valve and mild left ventricular hypertrophy.

Based upon the above information, you will now recommend :

- (A) Exercise stress test
- (B) Thallium Stress test
- (C) Coronary angiography followed by aortic valve replacement
- (D) Start anti-anginal therapy and follow by serial echocardiograms

A 9.

A 26-year-old male patient presents to the emergency room with history of palpitations of 2-hour duration. The physical examination reveals pulse 170/minute regular, BP 110/70, regular cannon waves on JVP are seen with each heart beat. The EKG is shown below :



Based upon the above information you will now recommend :

- (A) IV adenosine
- (B) IV procainamide
- (C) IV lidocaine
- (D) Cardioversion

A 10.

The physical examination of the heart in a patient with WPW will reveal the following finding:

- (A) Loud S1
- (B) Soft S1
- (C) Wide splitting of S2
- (D) Narrow splitting of S2

B 11

A 54-year-old black male with long standing history of hypertension presents with history of severe chest pain radiating to the back of 2 hour duration. The physical examination reveals BP 230/130 right arm and 170/ 80 in the left arm, pulse 100/minute and right carotid pulse is weaker than the left. An early diastolic murmur is heard over the left sternal border. The EKG shows evidence of left ventricular hypertrophy and ST elevation in the leads II, III, and AVF. The chest x-ray shows widening of the mediastinum. Based upon the above information, you will now recommend:

- (A) Sublingual nifedipine
- (B) IV beta blockers
- (C) IV diltiazem
- (D) Thrombolytic therapy

B 12

A 52-year-old white male consults you because of recurrent attacks of chest pain on exertion of 3 months duration. The pain lasts few minutes and relieved by rest. The physical examination is unremarkable and the resting EKG is normal. An exercise stress test shows 3 mm horizontal ST depression lasting > .08 seconds in leads V2-V5 during the fourth minute of a Bruce protocol at a heart rate of 90/minute (50% of maximum predicted). The test is terminated because of above findings. The ST depression persists for 10 minutes after exercise. Patient had no chest pain during the test.

Based upon the above information, you will now recommend:

- (A) Stress thallium study
- (B) Cardiac catheterization
- (C) No further diagnostic tests and start therapy with nitrites and beta blockers
- (D) Ambulatory electrocardiography monitoring

D 13

You are asked to evaluate a 26-year-old man who recently had a brief syncopal episode while playing football. He denies any palpitations, shortness of breath or chest pain. The physical examination reveals BP 130/80, pulse 76/minute with rapid carotid upstroke, CVS: S4 +, grade 4/6 crescendo-decrescendo systolic murmur heard best over the left sternal border. The murmur becomes louder with Valsalva's maneuver and standing and decreases in intensity with squatting.

Based upon the above information, the most likely diagnosis is :

- (A) Aortic stenosis
- (B) Ventricular septal defect
- (C) Atrial septal defect
- (D) Hypertrophic cardiomyopathy

C

14.

A 16-year-old boy comes to you for routine physical examination. He has been in excellent health and denies any complaints. He is physically very active and is the captain of his school's football team. Physical examination reveals BP 110/70, pulse 68/minute, CVS: S2 widely split and does not change with respiration, grade 2/6 mid-systolic murmur heard best in the pulmonary area and a mid-diastolic murmur heard over lower left sternal border. Based upon the above information the most likely diagnosis is :

- (A) Pulmonic stenosis
- (B) Ventricular septal defect
- (C) Atrial septal defect
- (D) Tricuspid stenosis

B

15.

A 46-year-old man is admitted to the CCU with a acute antero-septal myocardial infarction. He is given thrombolytic therapy and started on IV nitroglycerine, heparin, propranolol and aspirin. On the third hospital day, he develops sudden shortness of breath. Physical examination reveals rales in both lungs, loud grade 4/6 holosystolic murmur heard best over the left sternal border. The murmur does not change with respiration. A Swan -Ganz catheter is inserted and following data is obtained

RA pressure 12 mm Hg (nl 2-8), RV pressure 45/12 (nl : 20-25/6-12), PA 45/20 (nl: 20-25/ 4-8), PCW pressure 22 mm Hg (nl : 3-11)
O2 saturation: RA 72 % RV 84 % PA 85%

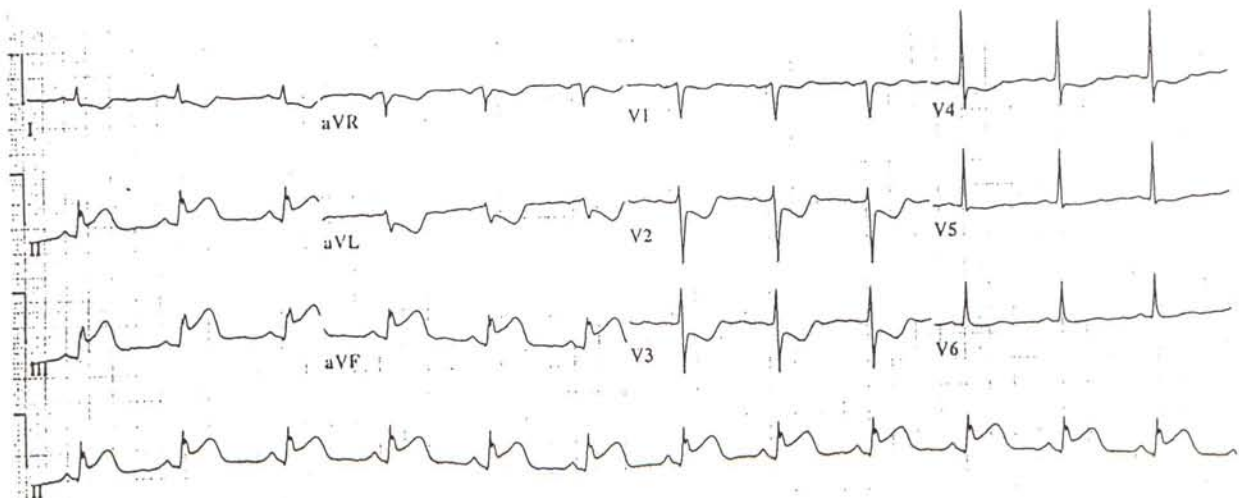
Based upon the above information, the most likely diagnosis is:

- (A) Rupture of papillary muscle
- (B) Rupture of interventricular septum
- (C) Rupture of interatrial septum
- (D) Rupture of chordae tendineae

O

16.

A 42-year-old male patient is admitted with a history of severe substernal chest pain of two-hour duration. Pain is associated with nausea and diaphoresis. Physical examination reveals jugular venous engorgement with a positive Kussmaul's sign, BP 82/60, pulse 90/min CVS : S4 +, no murmurs. Chest x-ray shows normal size heart and clear lung fields. EKG obtained on admission is shown below.



A Swan-Ganz catheter is inserted and following data is obtained :
RA pressure 18 mm (nl : 2-8), RV 25/18 (nl : 20-25/6-12), PA 22/8 (nl : 20-25/4-8), PCW 8 mm (nl : 6-12)
O2 saturation: SVC 74% RA 75% RV 74% PA 75%

All the statements about the above patient are correct except:

- (A) Best initial management of hypotension in this patient is volume loading
- (B) Leads V3 R and V4 R are likely to show ST elevation
- (C) Thrombolytic therapy should be given
- (D) Best initial management of hypotension in this patient is dopamine infusion

C 17.

A 68-year-old woman is brought to emergency room in confused and disorientated state. No other medical history is available. Physical examination reveals pulse 100/min, BP 80/60, temp. 99 F and marked mental confusion. EKG is normal except sinus tachycardia. Laboratory studies show Hb 9.5 g/dL, Hct 27 % WBC 12000 / uL, BUN 40 mg /dL and Cr 1.8 mg/dL. The chest x-ray is normal. A Swan-Ganz catheter is inserted and following data is obtained.
RA pressure 4 mm (nl: 2-8), RV pressure 20/4 (nl: 20-25/6-12), PA pressure 20/6 (nl: 20-25/4-8), PCW pressure 6 mm (nl: 6-12), cardiac output 5 L/minute/M2 (nl: 2.6 - 4.2), peripheral vascular resistance 325 Dyns/Cm 5 (nl : 700-1600)

Based upon the above information, the most likely cause of shock in this patient is

- (A) Massive pulmonary embolism
- (B) Cardiac tamponade
- (C) Septic shock
- (D) Hypovolumic shock due to blood loss or dehydration

D 18.

A 38-year-old woman presents with 4- months history of fatigue, increasing shortness of breath, ankle edema and abdominal swelling. She was born in China and has been living in this country for the last 3-years. Physical examination reveals engorged jugular veins with positive Kussmaul's sign, ++ ankle edema, ++ ascites, enlarged liver and a sharp early third heart sound. The chest x-ray shows normal cardiac size and increased pulmonary venous markings. The EKG shows low voltage in limb leads.

Echocardiogram: Normal chamber size, normal ventricular contractility, thickened pericardium and no pericardial effusion.

Right heart catheterization: RA pressure 16 mm (nl : 2-8), RV pressure 35/18 mm (20-25 /6-12), PA pressure 35/16 (nl : 20-25 / 4-8)
PCW pressure 16 mm (nl : 6-12)

Based upon the above information, you will now recommend :

- (A) Left heart catheterization
- (B) Endomyocardial biopsy
- (C) liver biopsy
- (D) Surgical stripping of pericardium

A

19.

A 42-year-old man presents with progressively increasing shortness of breath and marked weakness of 3 days duration. He has a history of chronic renal failure and has been on hemodialysis for the last one year. Physical examination reveals a BP 86/70 and the systolic pressure drops to 66 after deep inspiration, engorged neck veins, pulse 100/minute and a paradoxical pulse of 20 mm. CVS : Heart sounds are distant and no murmurs. EKG: Low voltage in limb leads
Echocardiogram: Pericardial effusion with right ventricular collapse in diastole
Chest x-ray: Cardiomegaly with clear lung fields
Right heart catheterization: RA pressure 14 mm (nl: 2-8), RV 35/ 15 (nl : 20-25/ 6-12), PA pressure 35/ 14 (nl : 20-25/4-8), PCW 14 mm (nl :6-12)
Based upon the above information, you will now recommend:
(A) Pericardiocentesis
(B) Pericardial stripping
(C) Broad spectrum antibiotics
(D) Intravenous heparin

B

20.

A 32-year-old female is brought to emergency room with history of progressively increasing shortness of breath of 6 hours duration. Physical examination reveals patient in moderate respiratory distress, BP 130/80, pulse 100 minute, Chest: rales up to both mid lung fields, CVS: S3 +, S4 + and a loud 4/6 pansystolic murmur heard best at the apex. The murmur decreases in intensity with inspiration and EKG shows sinus tachycardia with non-specific ST & T wave changes. Rt heart catheterization reveals the following results.
RA pressure 10 mm (nl: 2-8), RV pressure 28/14 (nl : 20-25/ 6-12), PA 28/ 18 (nl : 20-25/4-8), PCW 18 mm (nl : 6-12) and prominent V waves
Based upon the above information, the best initial management should be :
(A) IV diuretics, digoxin and ACE inhibitor
(B) Beta blockers
(C) Immediate valve replacement
(D) IV nitroprusside

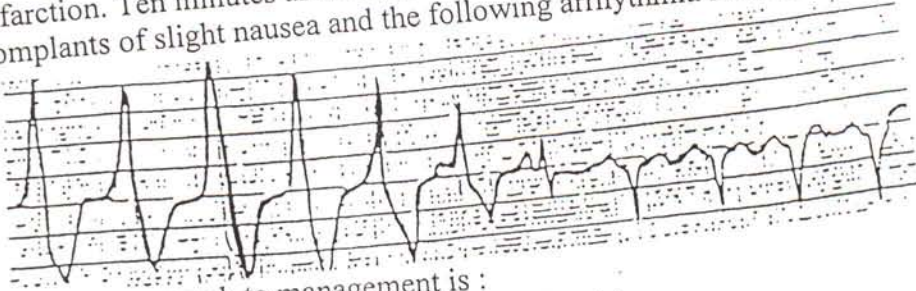
C

21.

A 55-year-old man consults you for evaluation of recurrent attacks of chest pain which occur with exertion. The physical examination is unremarkable and resting EKG is normal. Exercise stress test reveals 3mm horizontal ST depression in anterior leads during stage 2 of Bruce protocol and at a heart rate of 100/minute. The test is terminated because of chest pain. The ST depression persists up to 10 minutes after exercise. The coronary angiography is performed and it reveals triple-vessel coronary disease with left ventricular ejection fraction of 32%
Based upon the above information, You will now recommend :
(A) Coronary angioplasty
(B) Medical therapy and intensive risk modification program
(C) Coronary bypass surgery
(D) Intensive medical therapy and exercise thallium study after 6 weeks

D 22.

A 50-year-old black male is admitted with a acute inferior wall myocardial infarction. Ten minutes after completion of thrombolytic therapy, the patient complants of slight nausea and the following arrhythmia is noted on the monitor.




The best approach to management is :

- (A) IV lidocaine bolus followed by lidocaine drip
- (B) IV procainamide bolus followed by drip
- (C) Over drive pacing
- (D) Observation

D 23.

A 44-year-old patient is admitted because of acute anterior wall myocardial infarction. He is treated with thrombolytic therapy, heparin, aspirin and propranolol. His course in the hospital is uncomplicated. A stress test shows no evidence of ischemia and resting gated blood pool study shows a left ventricular ejection fraction of 52%. The night before discharge, the following arrhythmia is noted on the monitor

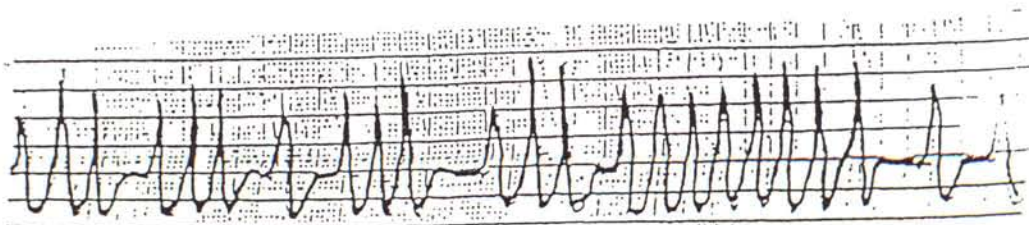


Based upon the above information, you will now recommend :

- (A) IV lidocaine
- (B) IV procainamide
- (C) Cardiac catheterization and EP studies
- (D) Discharge patient on aspirin and propranolol

C 24.

A 32-year-old patient presents to emergency room with history of palpitations of 3-hour duration. She is alert and oriented and denies any chest pain or shortness of breath. Physical examination reveals BP 130/80 and a irregular pulse of 160/minute. The EKG rhythm strip is shown below

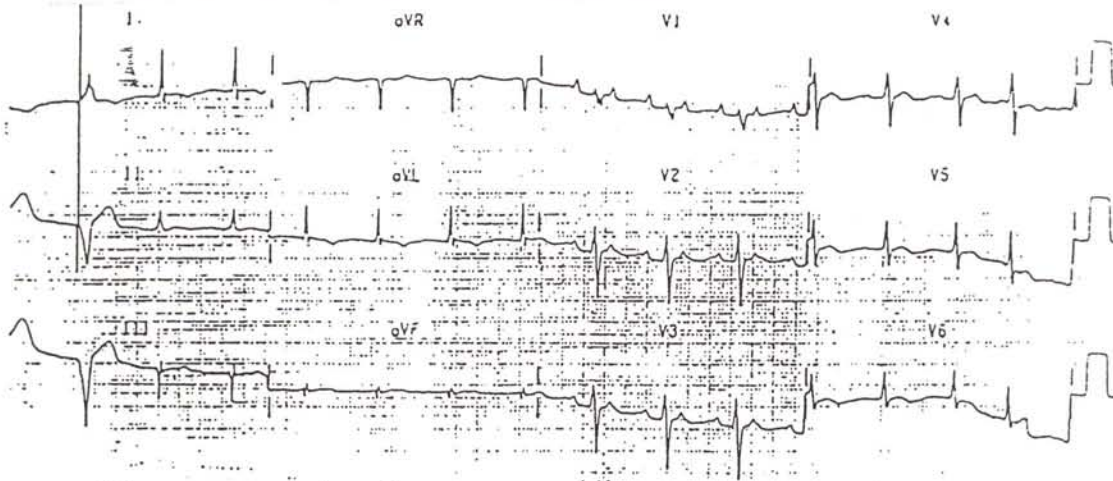


The best initial management for this patient should be:

- (A) IV digoxin
- (B) IV propranolol
- (C) IV procainamide
- (D) Cardioversion

25.

A 62-year-old patient comes to emergency room with history of nausea, weakness and palpitations of few days duration. She has been on digoxin, furasamide and captopril for congestive heart failure secondary to idiopathic cardiomyopathy. Her vital signs are stable and EKG is shown below:



The most appropriate therapy should be :

- (A) IV adenosine
- (B) IV procainamide
- (C) IV lidocaine
- (D) Hold digoxin and measure digoxin level

26.

A 44-year-old female is brought to emergency room after passing out at home. She was recently started on quinidine for control of frequent premature beats found on holtor monitor. She is fully alert and her vital signs are stable. EKG on admission is normal. One hour later, the monitor shows the following arrhythmia,




All of the following may be useful in the treatment of this patient except :

- (A) Increase dose of quinidine and start lidocaine drip for 24 hours
- (B) Atrial or ventricular over drive pacing
- (C) Magnesium
- (D) Discontinue quinidine

27.

A 56-year-old patient comes to emergency room because of progressively increasing cough and shortness of breath. He is known to have COPD and has been on theophyllin and inhaled bronchodilators. The arterial blood gas analysis show PO₂ 52 mm Hg, PCO₂ 62 mm Hg, pH 7.25. The EKG rhythm is shown below




All of the following treatment will be helpful in the treatment of above arrhythmia except

- (A) Supplemental O₂ or mechanical ventilation
- (B) Verapamil
- (C) Digoxin
- (D) Reducing theophyllin dose

28.

A 54-year-old male patient presents to emergency room because of one hour history of palpitations. He has a history of anterior wall myocardial infarction about 2 years ago and has been on aspirin, isosorbide and propranolol. The physical examination reveals patient to be diaphoretic, BP 120/80, pulse 148/minute regular, Chest : Clear, CVS : S1 & S2 normal, no murmurs. The EKG is shown below



Based upon the above information, the most appropriate treatment at this time is :

- (A) IV Adenosine
- (B) IV Amiodorone
- (C) IV lidocaine
- (D) Cardioversion

C 29.

A 34-year-old female consults you because of gradually increasing exertional dyspnea for the last one year. Physical examination reveals engorged neck veins, +++ edema of legs, liver 3 cm enlarged below rt costal margin, CVS : S1 normal, S2 (P2>A2) , grade 4/6 pansystolic murmur which increases with inspiration & heard best at LSB, Chest : clear

EKG : RVH with right axis

Right heart catheterization : RA pressure 16 mm (nl : 2-8), RV pressure 60/16 (nl :20-25/6-12), PA pressure 60/20 (nl : 20-25/4-8), PCW pressure 10 mm (nl : 6-12) ECHO : Right ventricular hypertrophy, no valvular abnormality

Lung scan:Diffuse patchy perfusion defects, no segmental or subsegmenta defects.

Based upon the above information, You will now recommend :

(A) Pulmonary angiography

(B) IV heparin

(C) Nifedipine and diuretics

(D) Propranolol

B

30.

A 72-year-old woman is brought to the emergency room because of shortness of breath. She has a past history of hypertension and has been on hydrochlorothiazide for many years. Physical examination reveals BP 180/100, pulse 110/minute, engorged neck veins, rales over both lung fields up to mid scapula, CVS : + S3, + S4, no murmurs

EKG : Left ventricular hypertrophy Chest x-ray : Pulmonary edema pattern

ECHO : Concentric left ventricular hypertrophy, normal ventricular contractility

RGBPS : Left ventricular ejection fraction 54%

The patient is initially treated with intravenous diuretics with improvement in symptoms

Based upon the above information, you will now recommend therapy with :

(A) Digoxin and ACE inhibitor

(B) A beta blocker

(C) Nifedipine

(D) Digoxin and oral nitrates

D

31.

A 54-year-old patient consults you for cardiac evaluation. He was found to have a heart murmur on a routine pre-employment physical examination. He denies any symptoms Physical examination reveals BP 140/60, pulse 80/minute, CVS : 3/6 early diastolic murmur at the base and left sternal border and a 2/6 ejection systolic murmur heard best in the aortic area which radiates to both carotids.

Echocardiogram shows evidence of severe aortic regurgitation with mild left ventricular dilatation. The resting gated blood pool study shows a left ventricular ejection fraction of 56%.

Based upon the above information, you will now recommend :

(A) Cardiac catheterization with coronary angiography

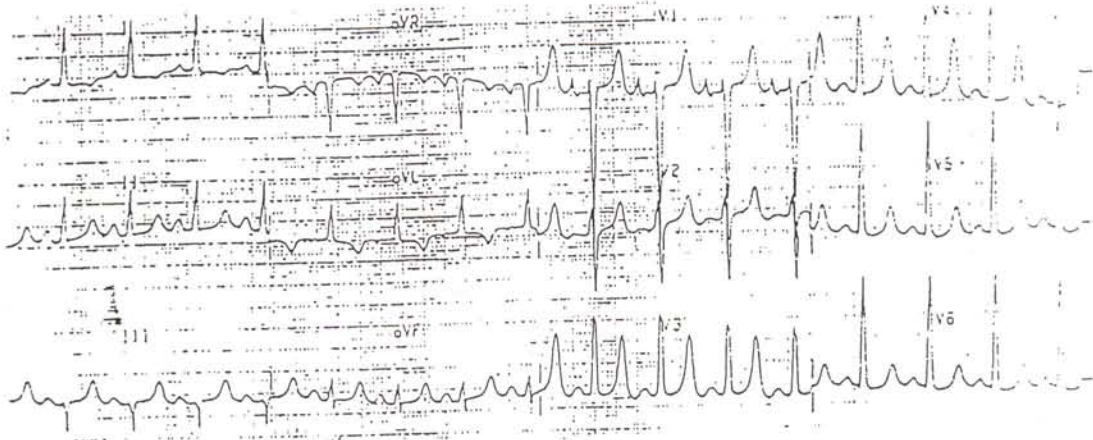
(B) Aortic valve replacement

(C) Beta blockers

(D) Medical follow-up and repeat echo and gated blood pool study in one year

32.

A 67-year-old female patient with past medical history of diabetes, hypertension and mild renal disease presents to the emergency room with generalized weakness. She has been on glyburide and captopril. Her EKG is shown below



The best initial management should be :

- (A) IV glucose plus insulin
- (B) Atropine
- (C) IV calcium gluconate
- (D) IV lidocaine

Directions : Questions (33-50) are true and false questions. Mark T for statements that are true and F for statements that are false

33-35 The endocarditis prophylaxis is indicated in the following patients

- F (33) Patient with aortic stenosis prior to dental extraction
- F (34) Patient with prolapse mitral valve with mitral regurgitation prior to colonoscopy
- F (35) Patient with VSD repaired 2 years ago prior to cystoscopy

36-39 True statements about obstructive cardiomyopathy include:

- F (36) The gradient across the left ventricular outflow tract correlates with symptoms and risk of sudden death
- T (37) The dyspnea is caused by the LV diastolic dysfunction
- T (38) Patient should not be allowed to participate in the vigorous sport activities
- T (39) The midsystolic murmur becomes louder on standing and Valsalva's

40-42 Anticoagulation with warfarin is indicated for the following patients with atrial fibrillation

T (40) A 76-year-old man with nonvalvular atrial fibrillation and prior history of TIA

T (41) A 50-year-old man with mitral stenosis and atrial fibrillation

T (42) A 78-year old man with idiopathic congestive cardiomyopathy, diabetes and atrial fibrillation

43-46 Drugs which have been shown to improve survival after MI include :

T (43) Aspirin

T (44) Beta blockers

F (45) Calcium blockers in Q wave infarction

T (46) Thrombolytic therapy

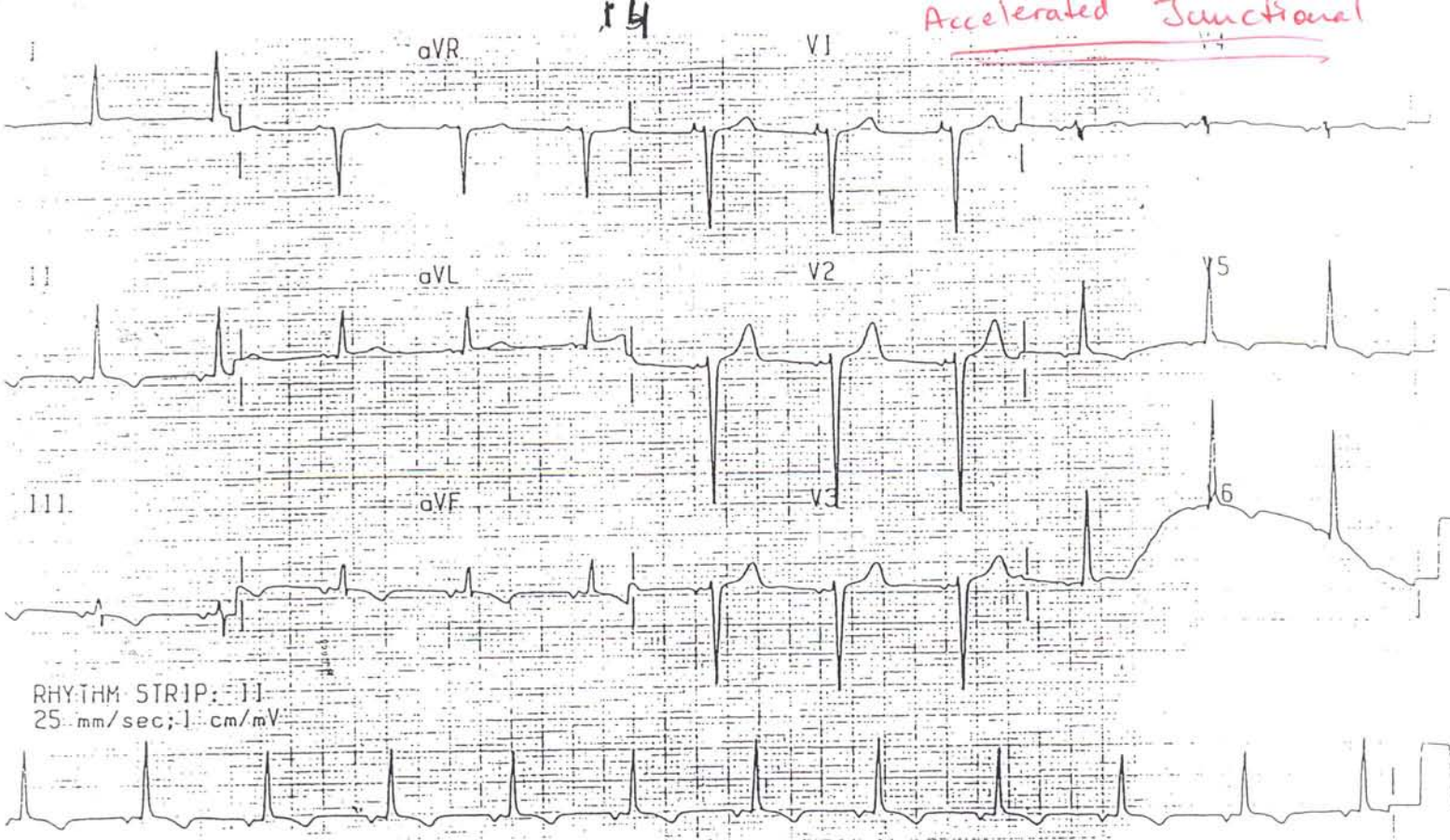
47-50 Select the drugs capable of causing the proarrhythmic effect:

T (47) Quinidine

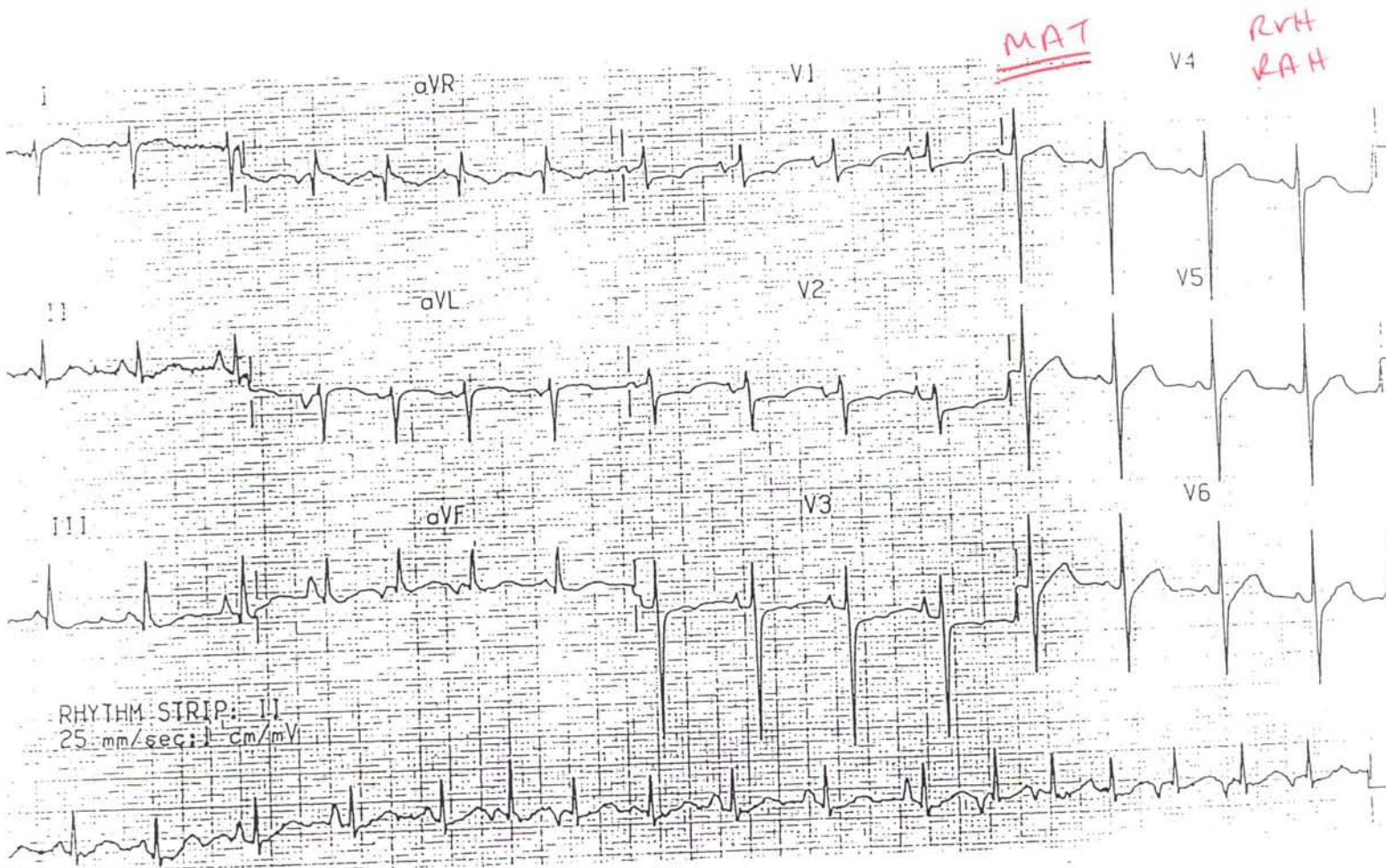
T (48) Procainamide

T (49) Sotalol

F (50) Beta blockers



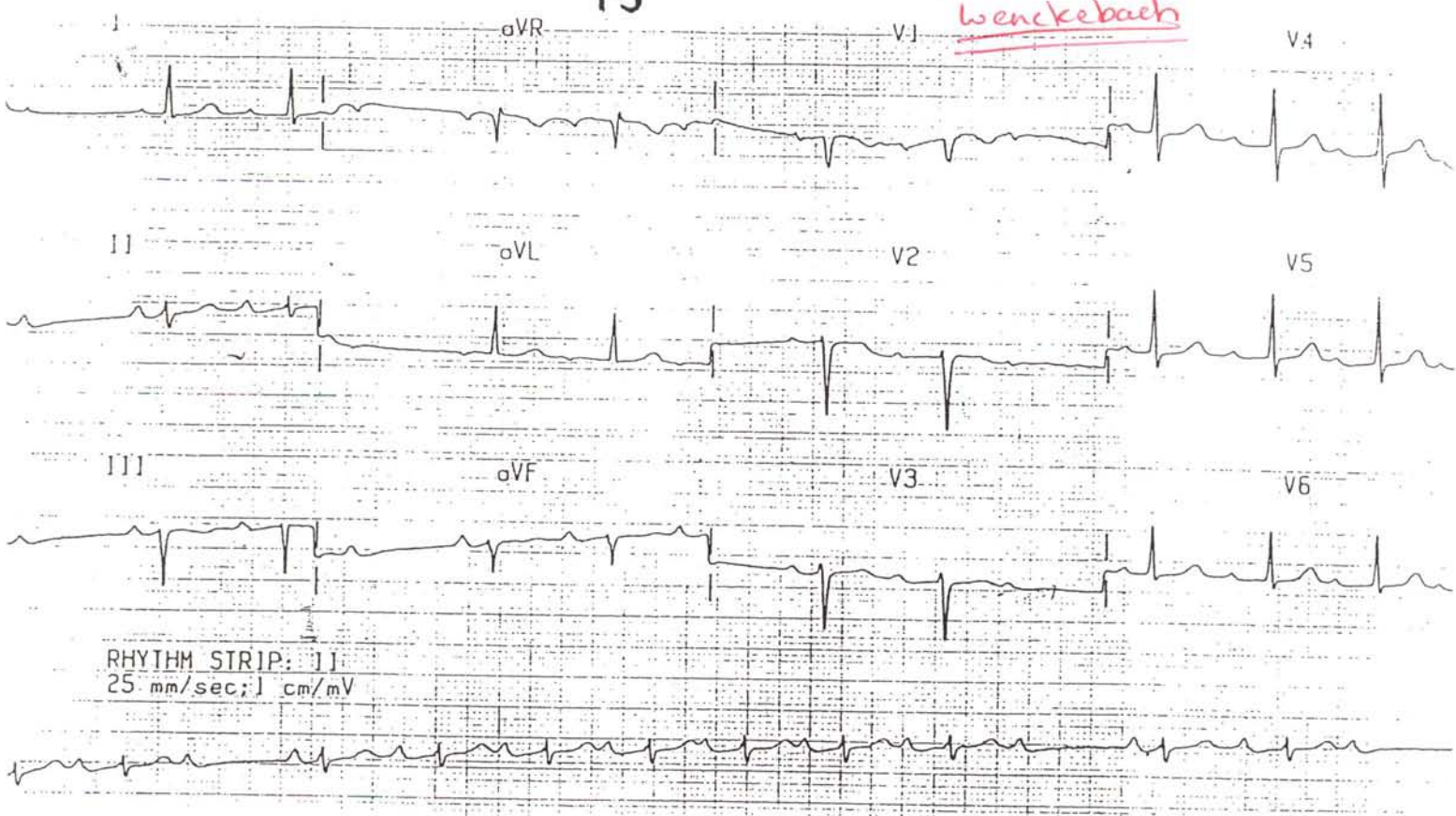
1



2

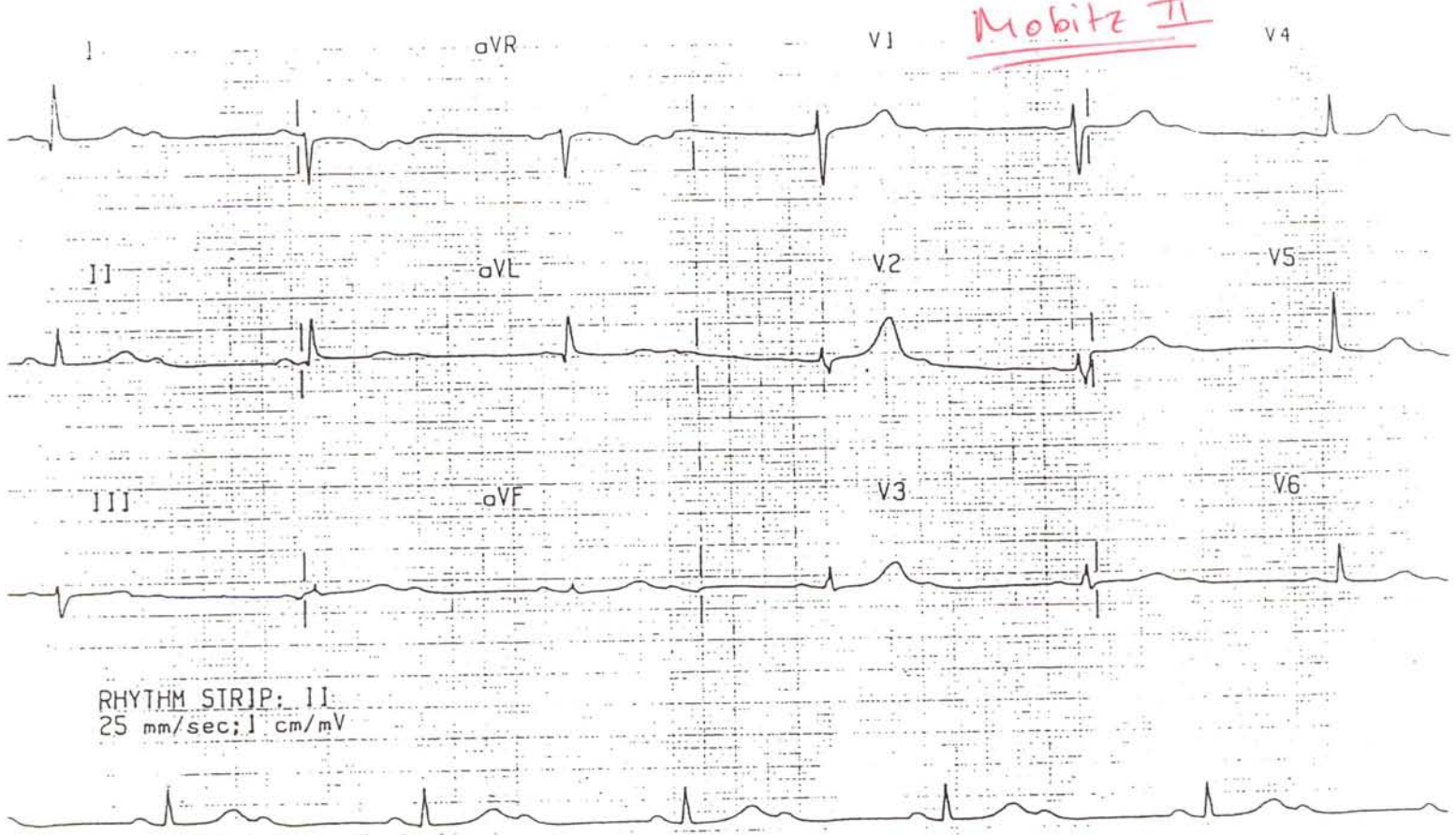
15

Wenckebach



3

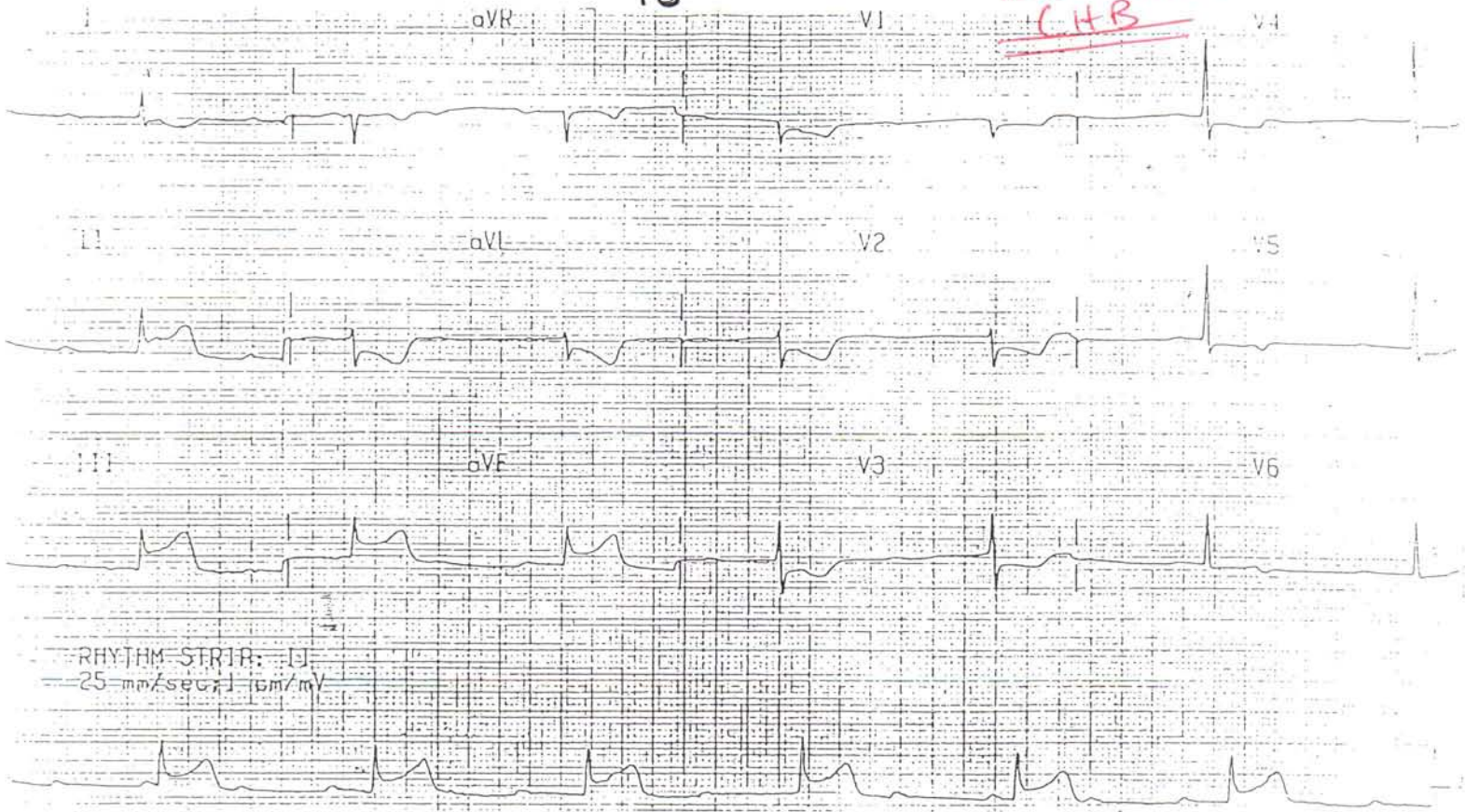Mobitz II



4

16

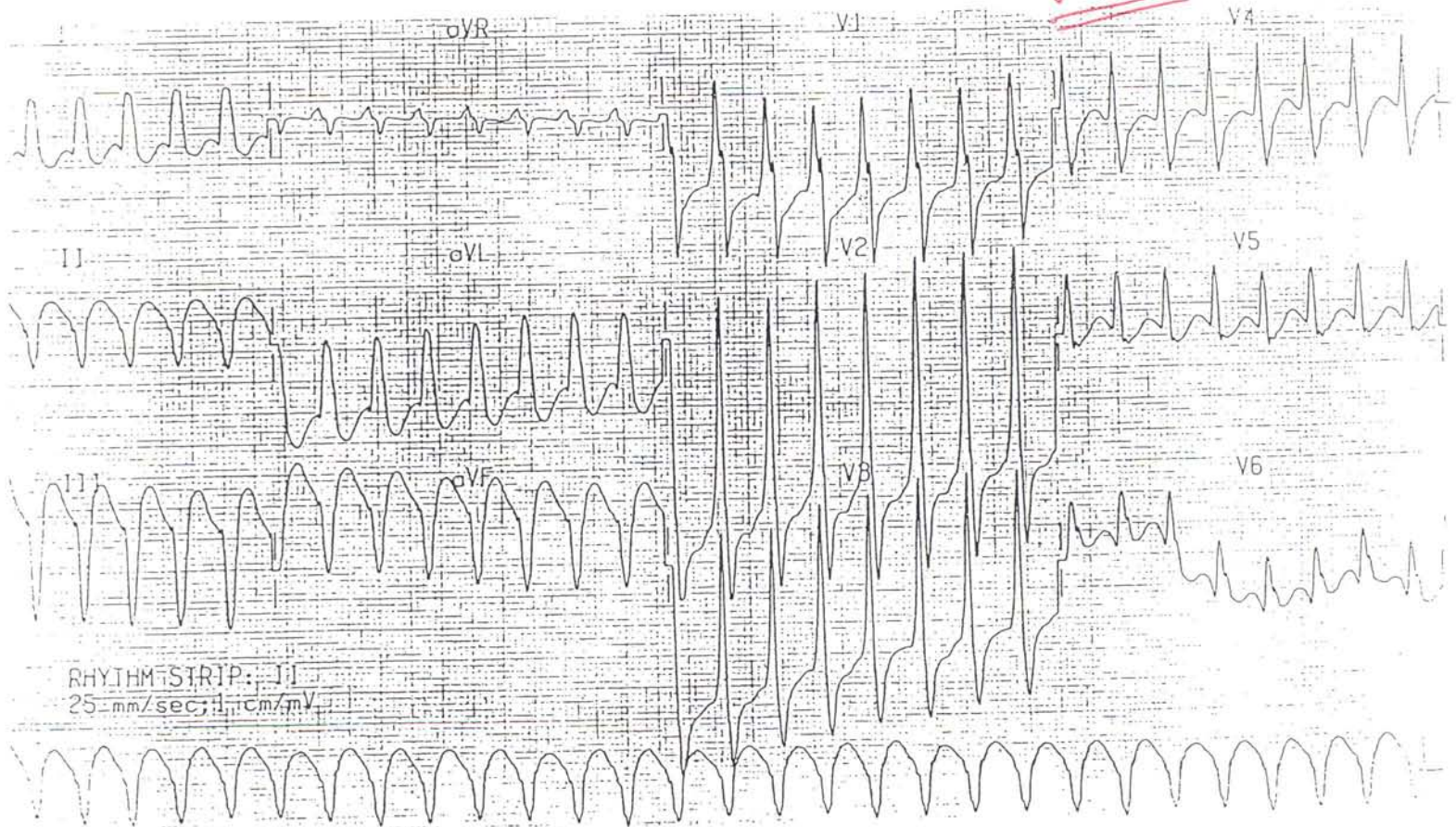I W STEMI
CHB



RHYTHM STRIP: J1
25 mm/sec; 1 cm/mV

5

V Tach

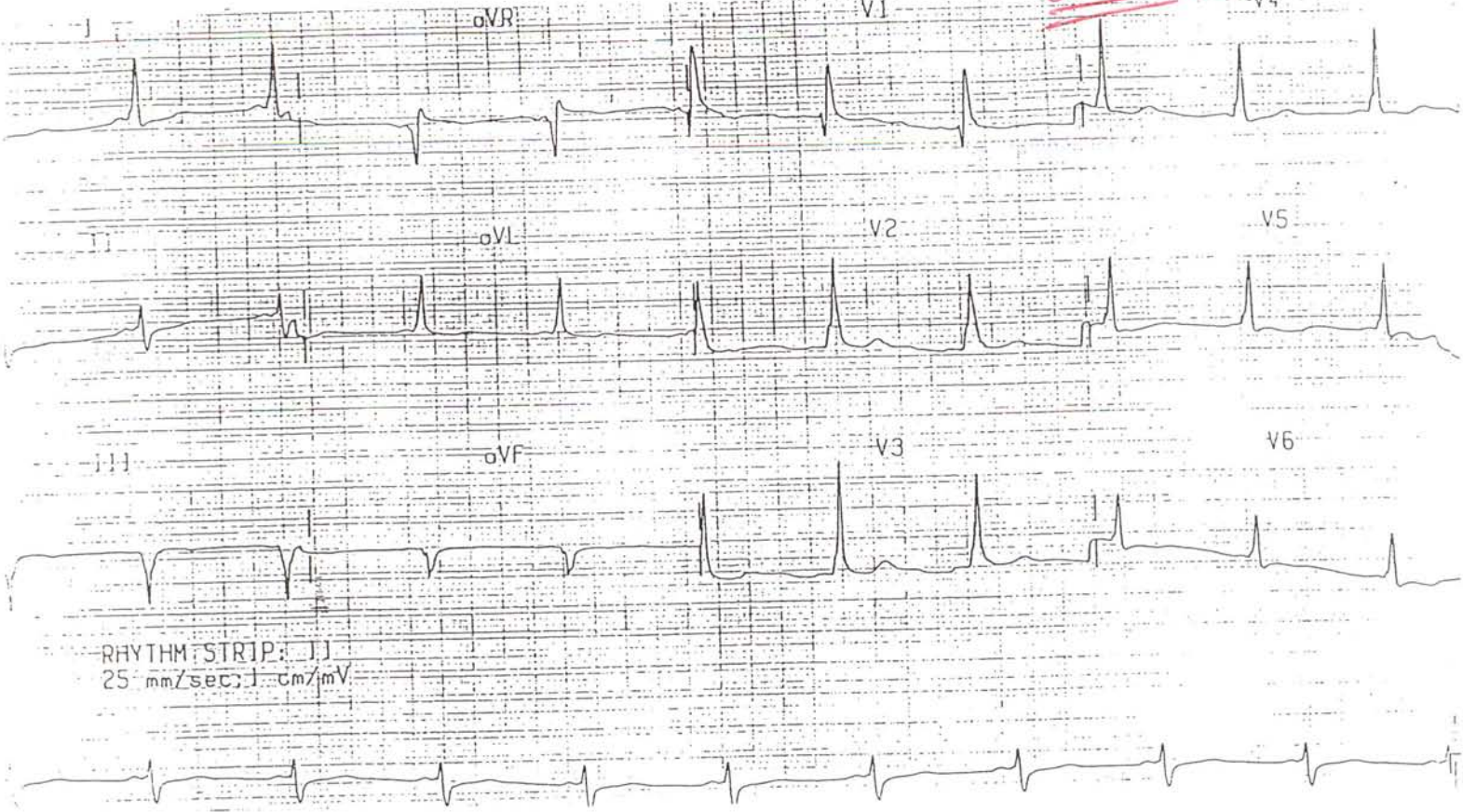


RHYTHM STRIP: J1
25 mm/sec; 1 cm/mV

6

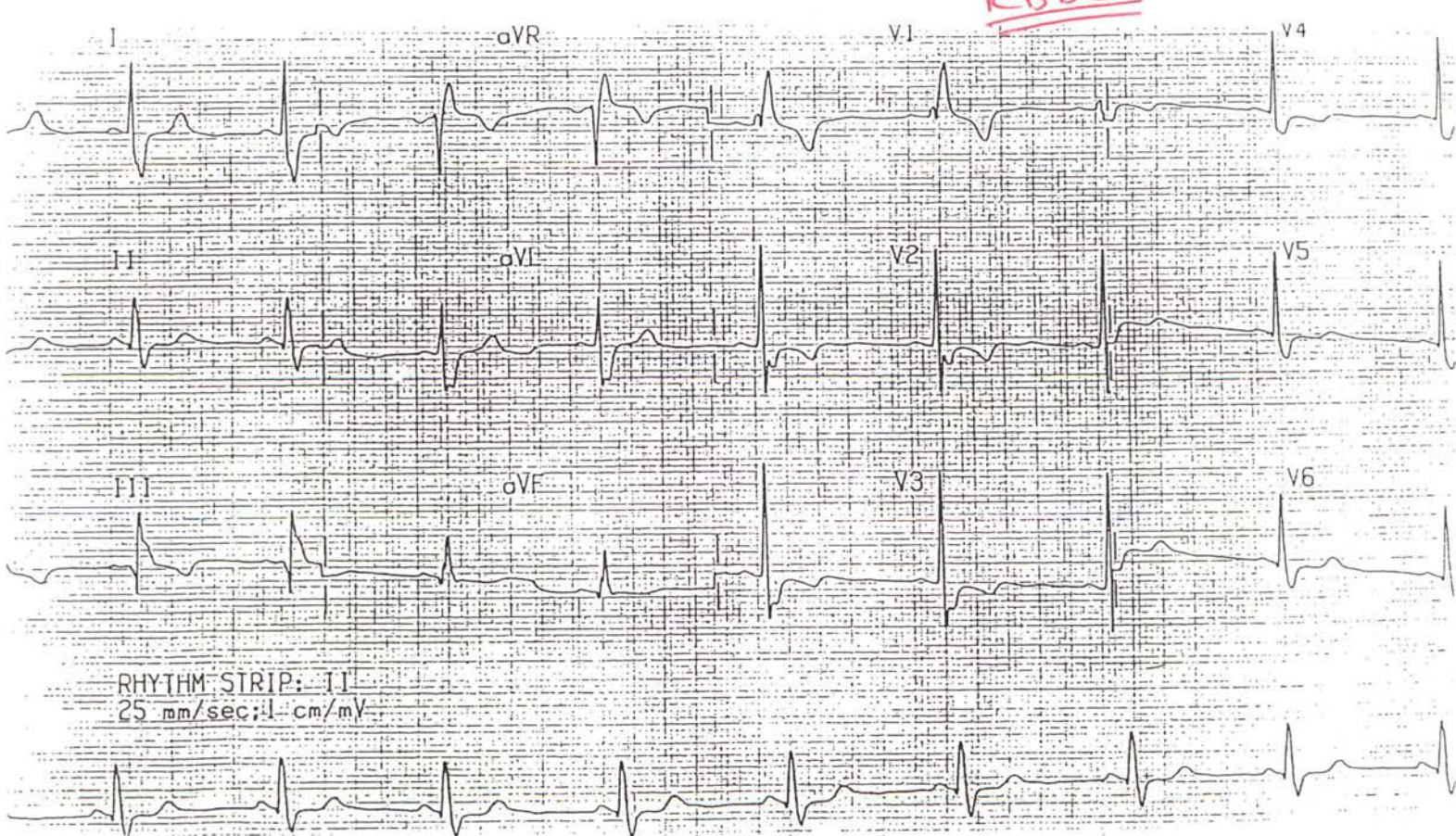17

LoPW (Type A)



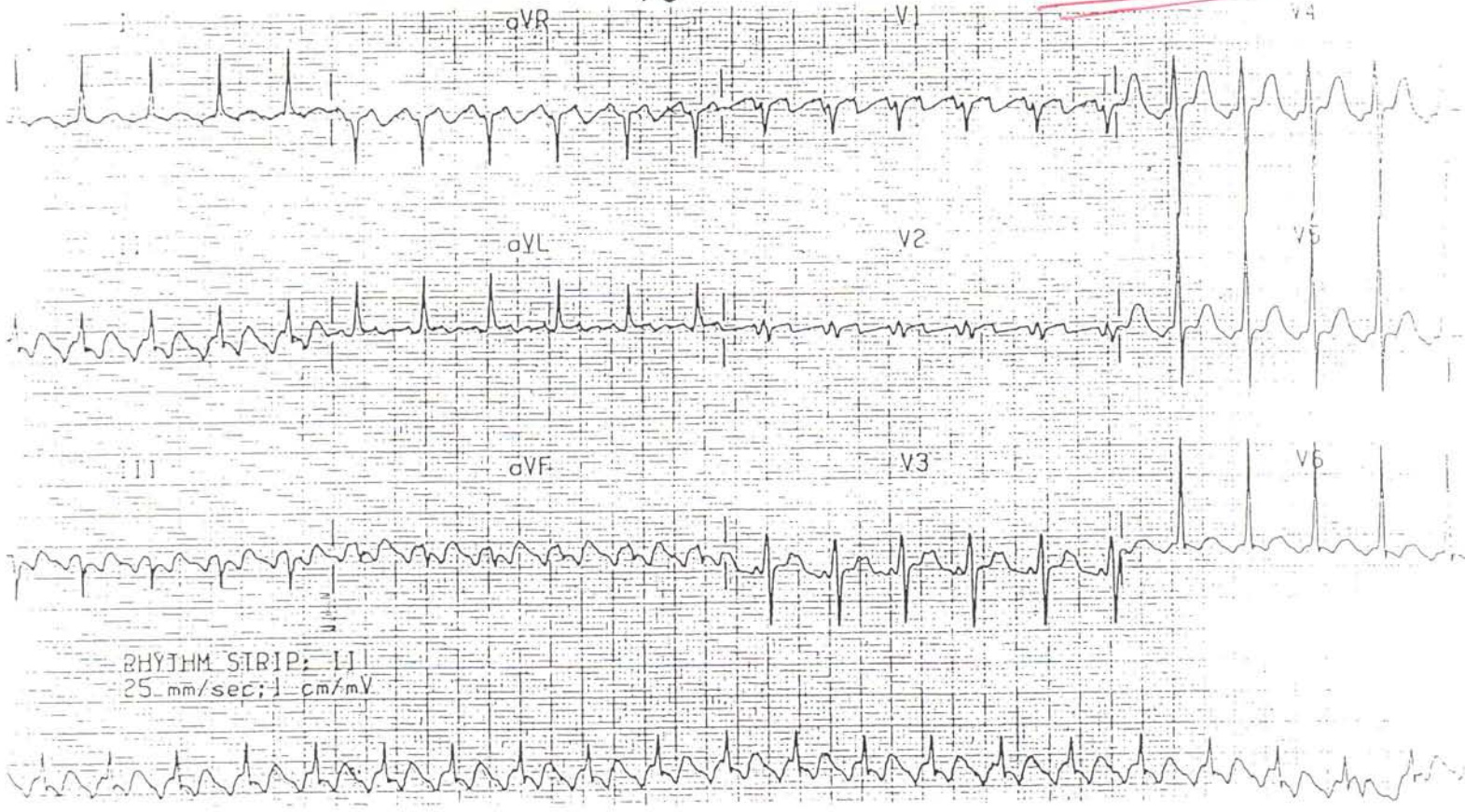
7

RBBB

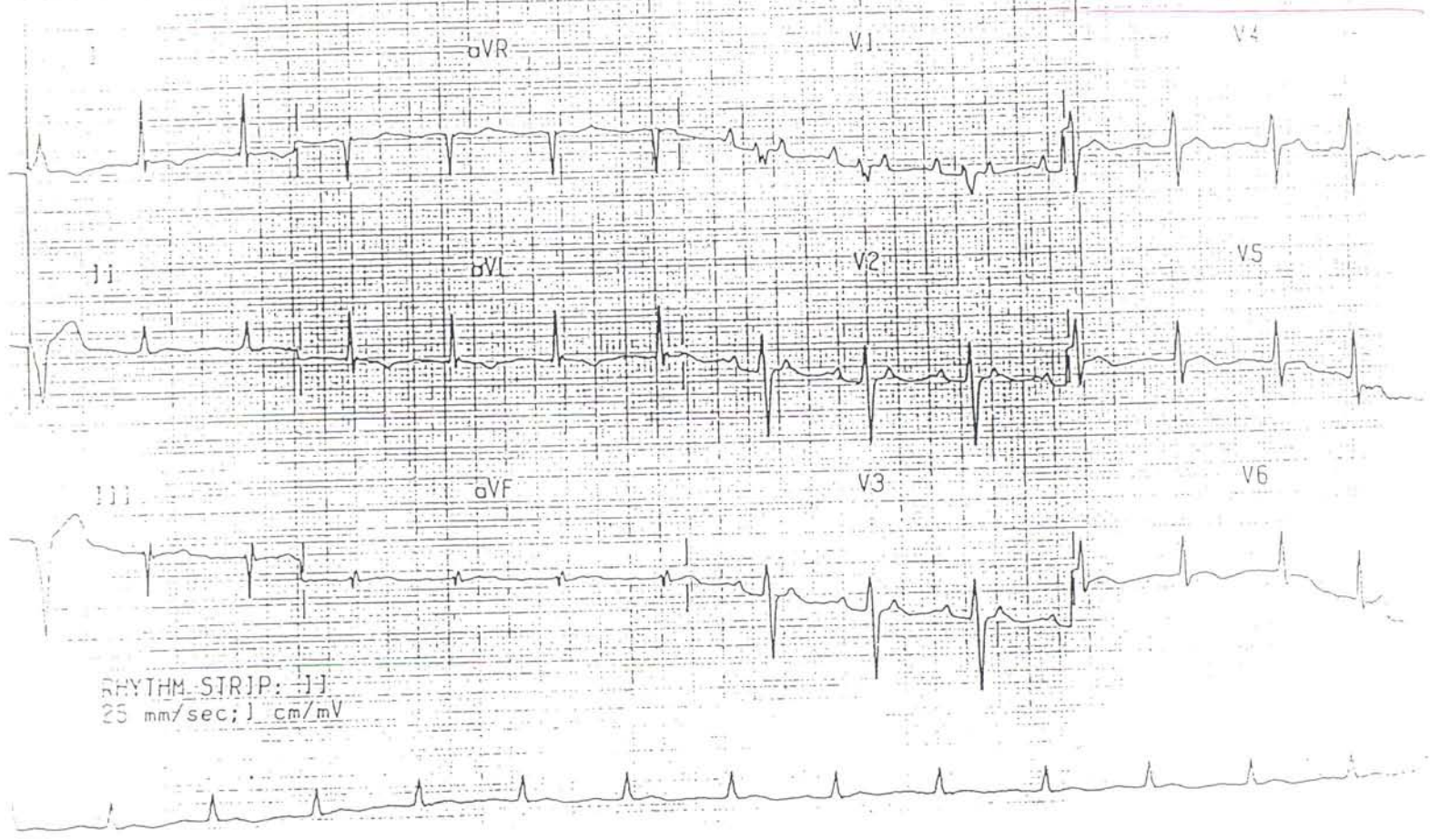


18

2:1 Aflutter

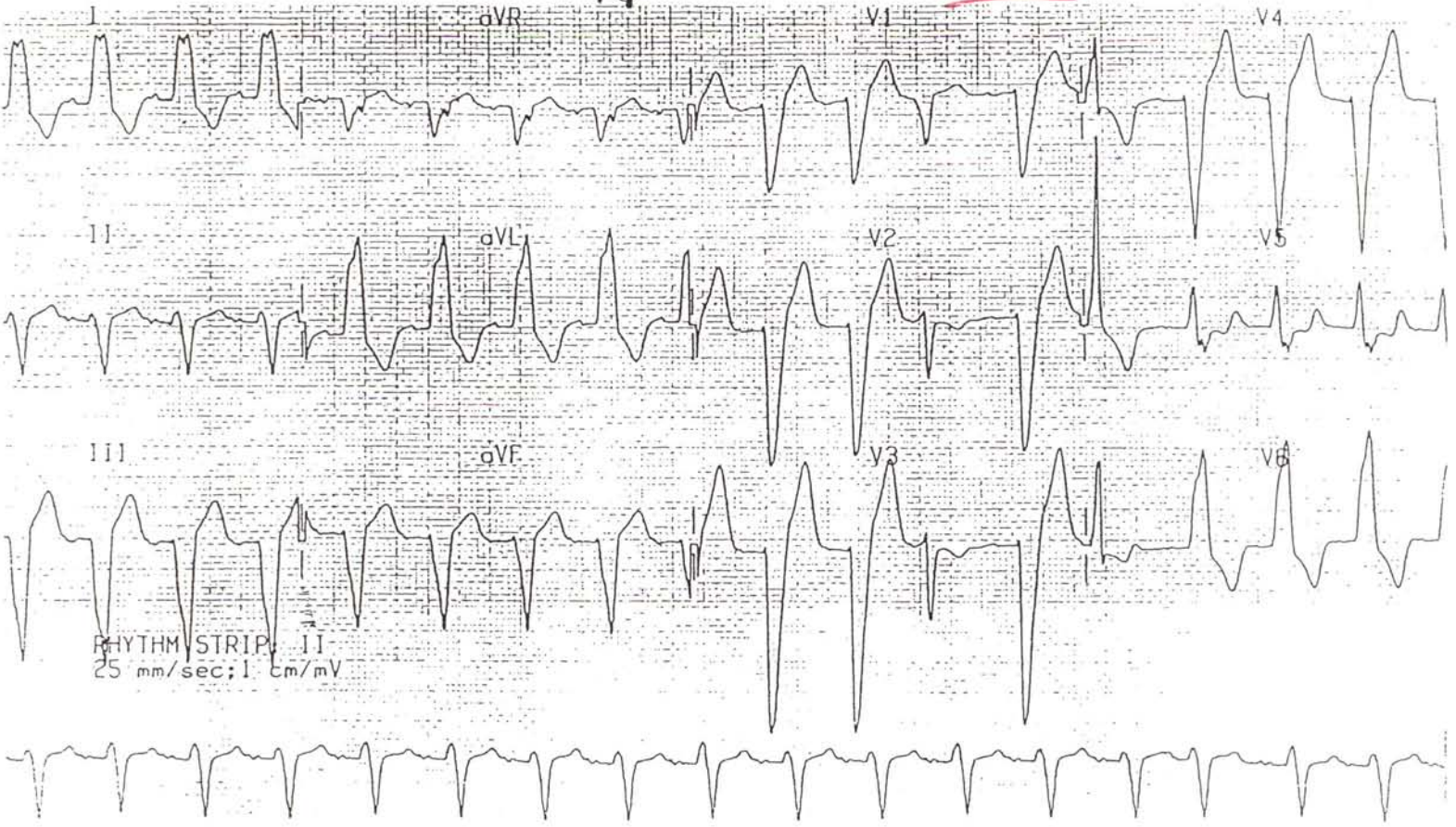

Atrial Tachycardia w/ 2:1 Block



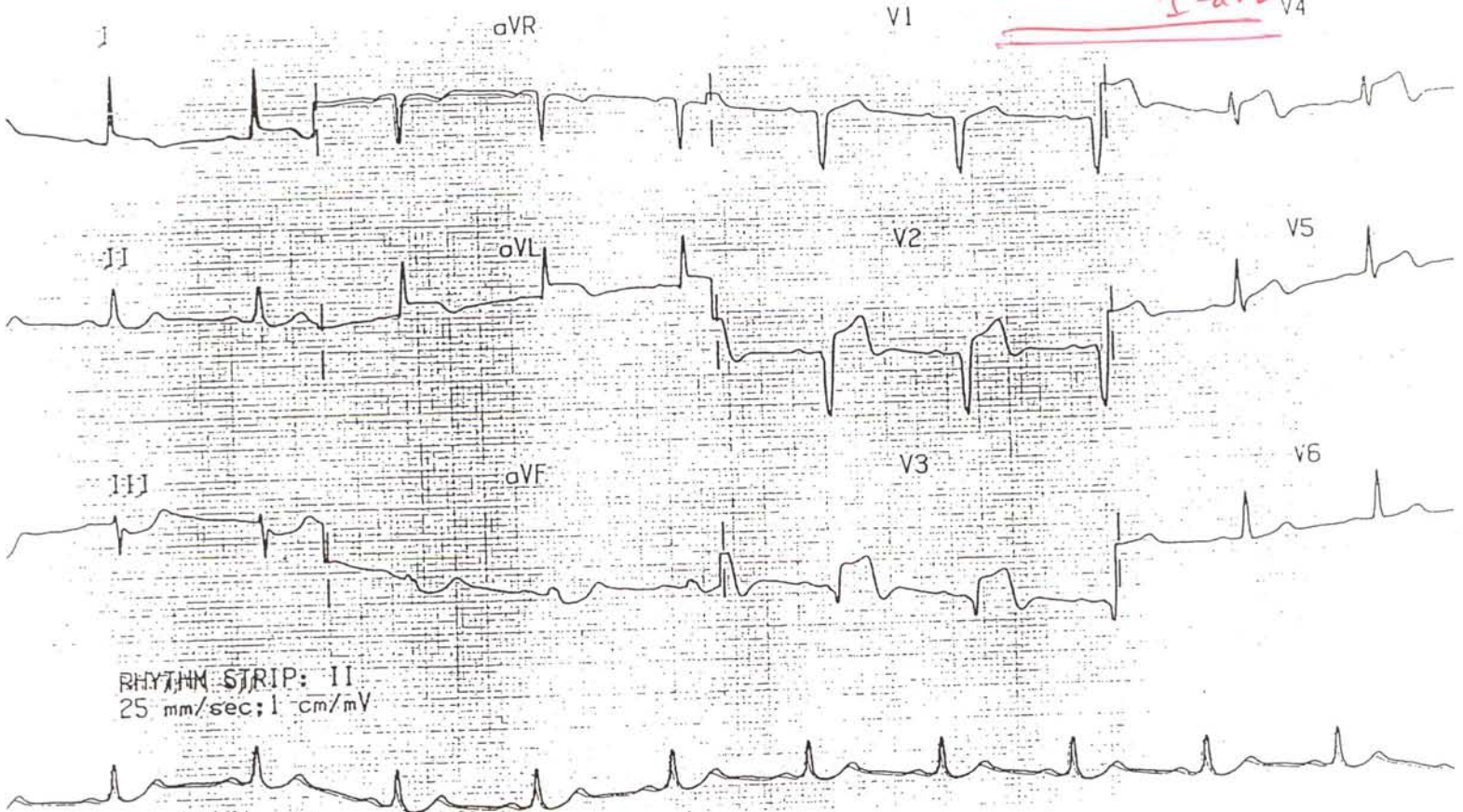
10

LRBB



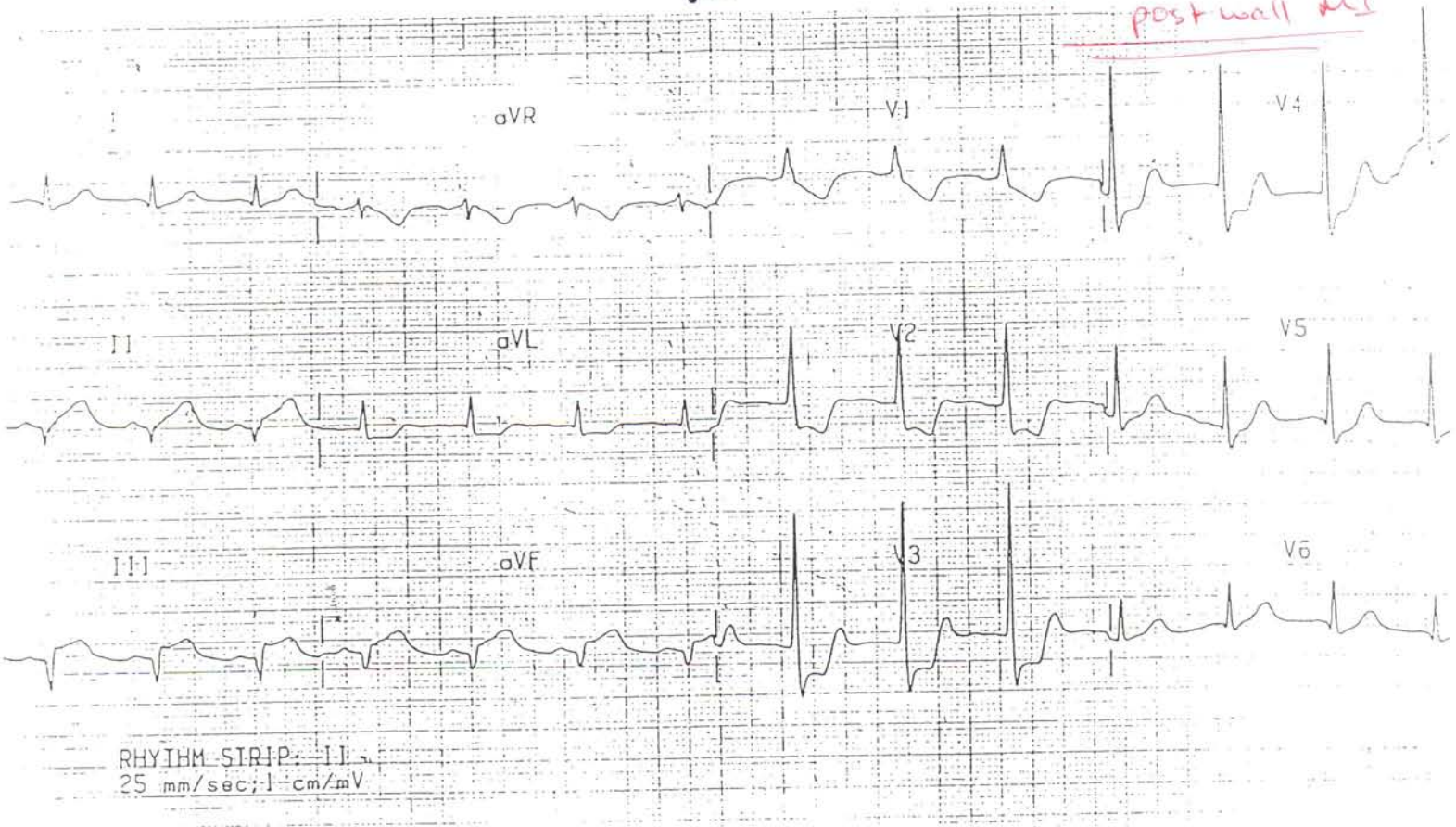
11

STEMI V2-V4 I-aVL



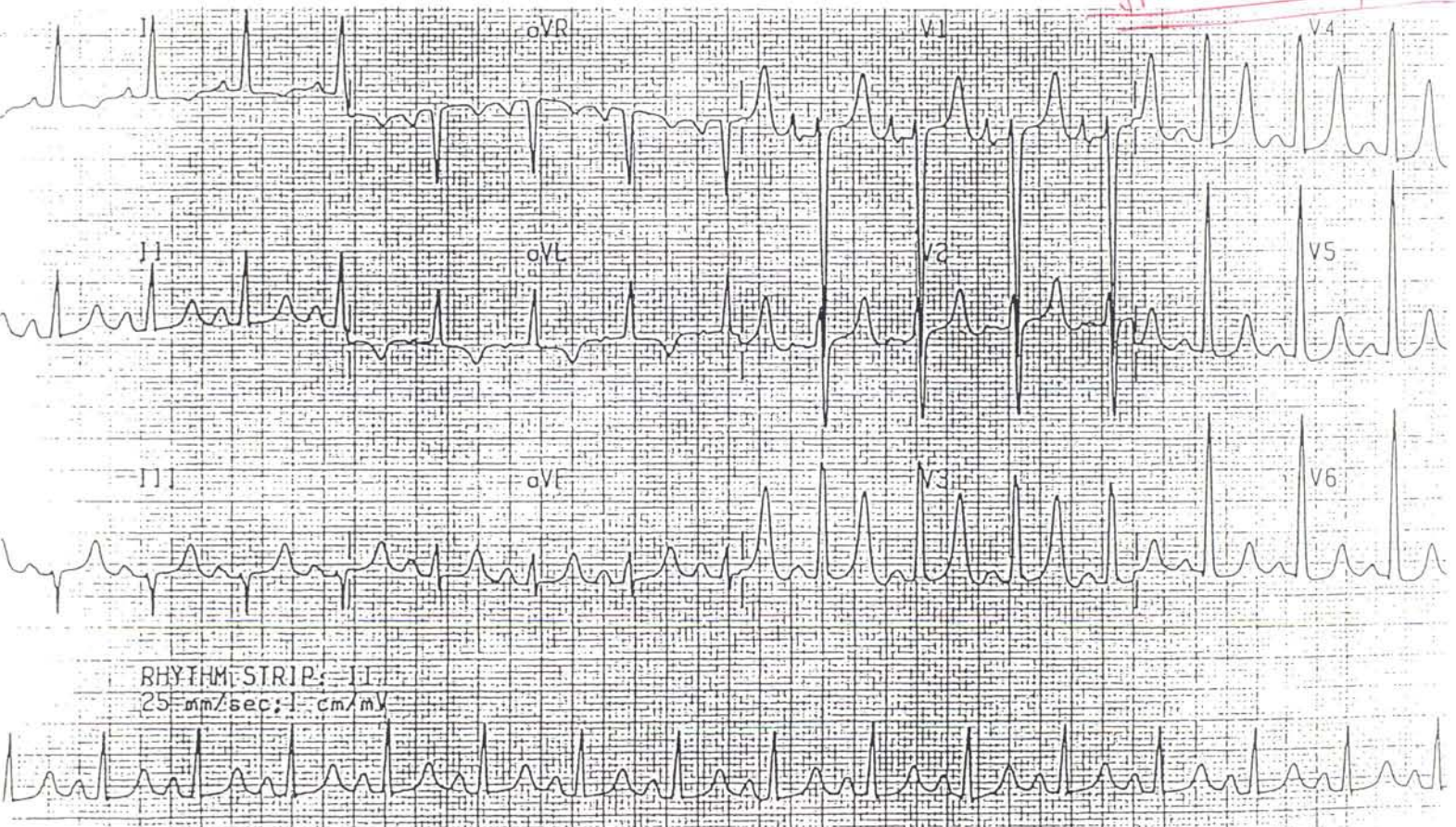
20

Iw STEMI w/
post wall MI



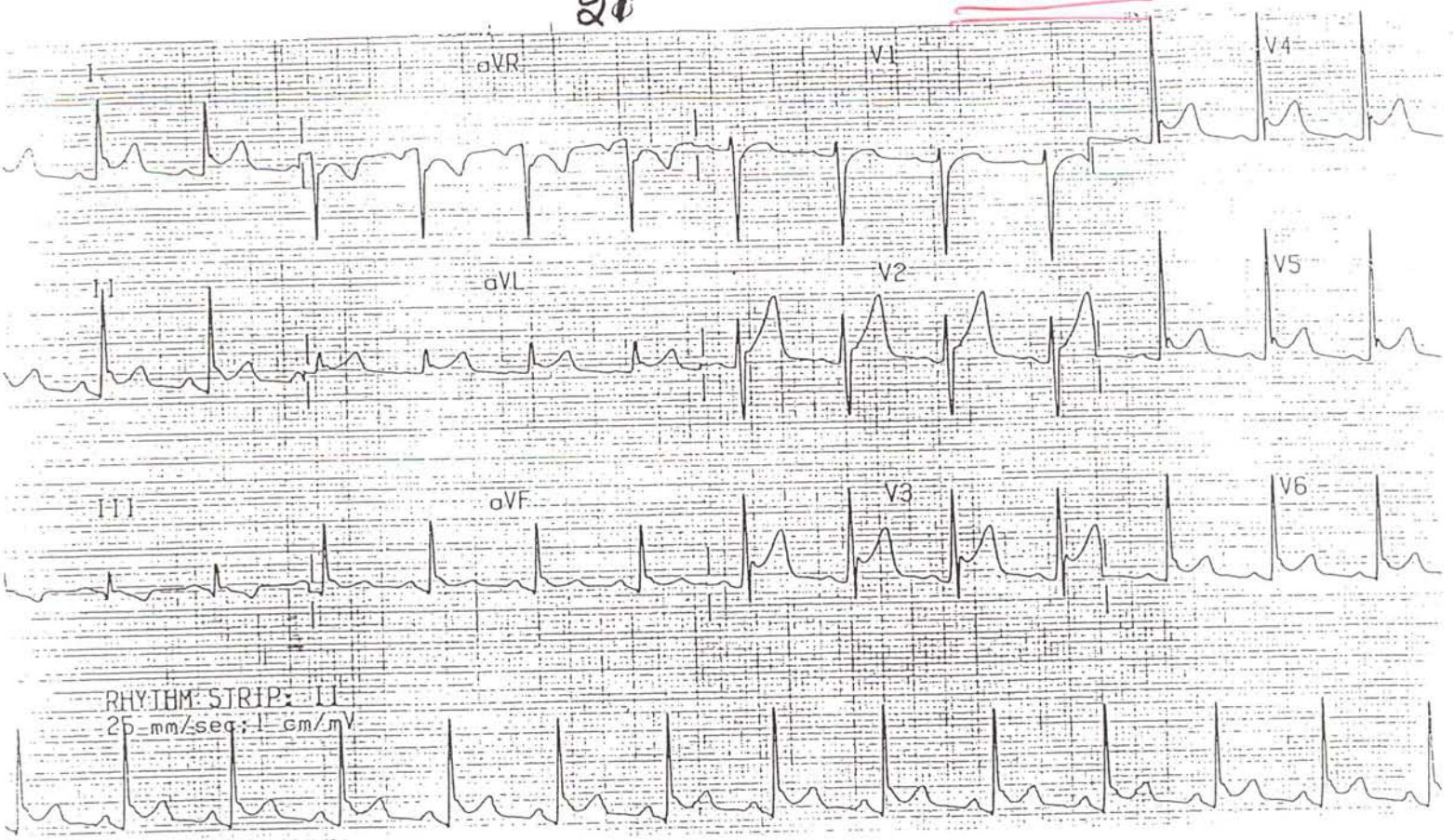
13

Hyperkalemia w/ LVH



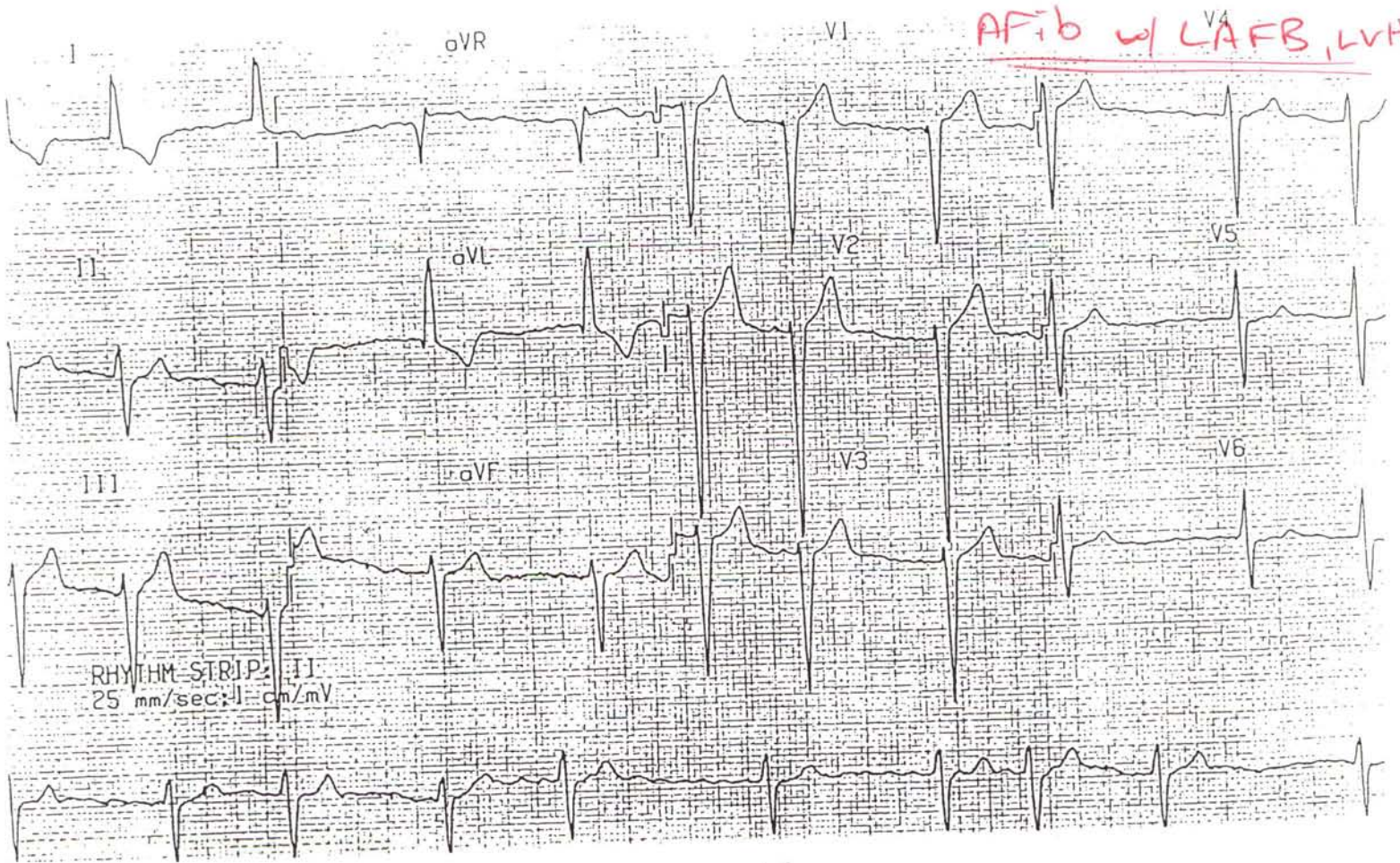21

Pericarditis



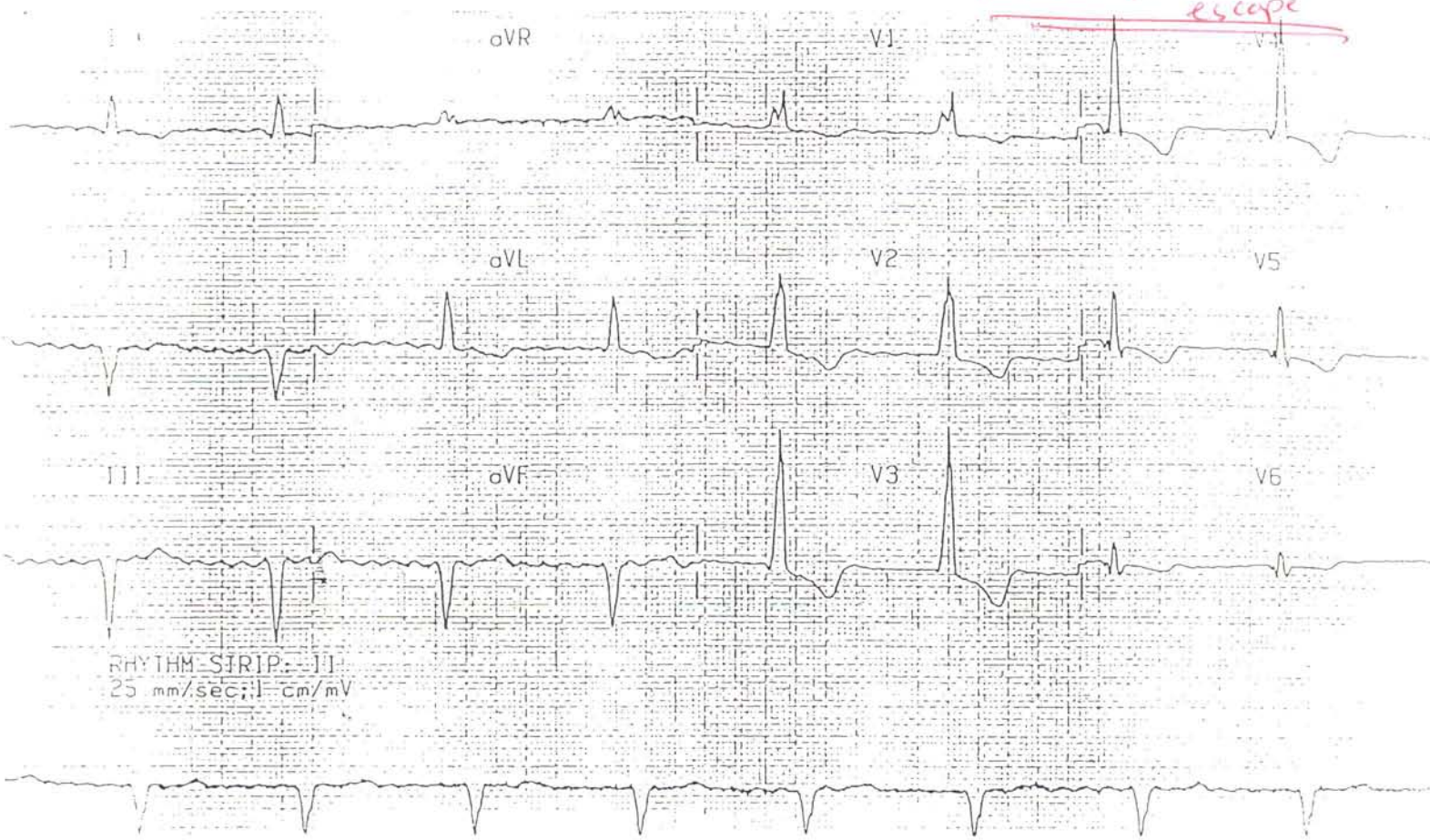
15

AFib w/ LAFB, LVH



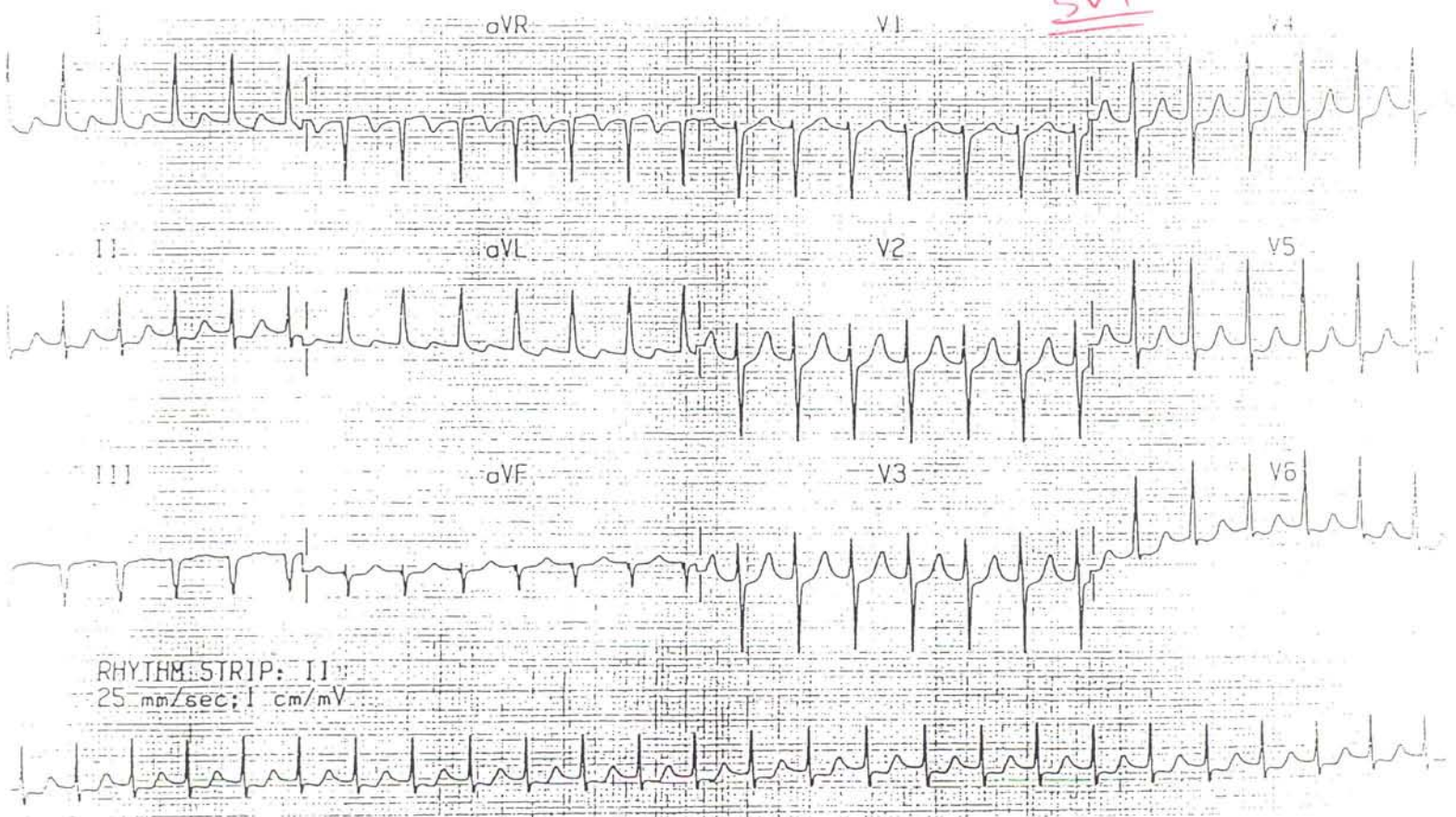
22

AFib w/ accelerated
escape



17

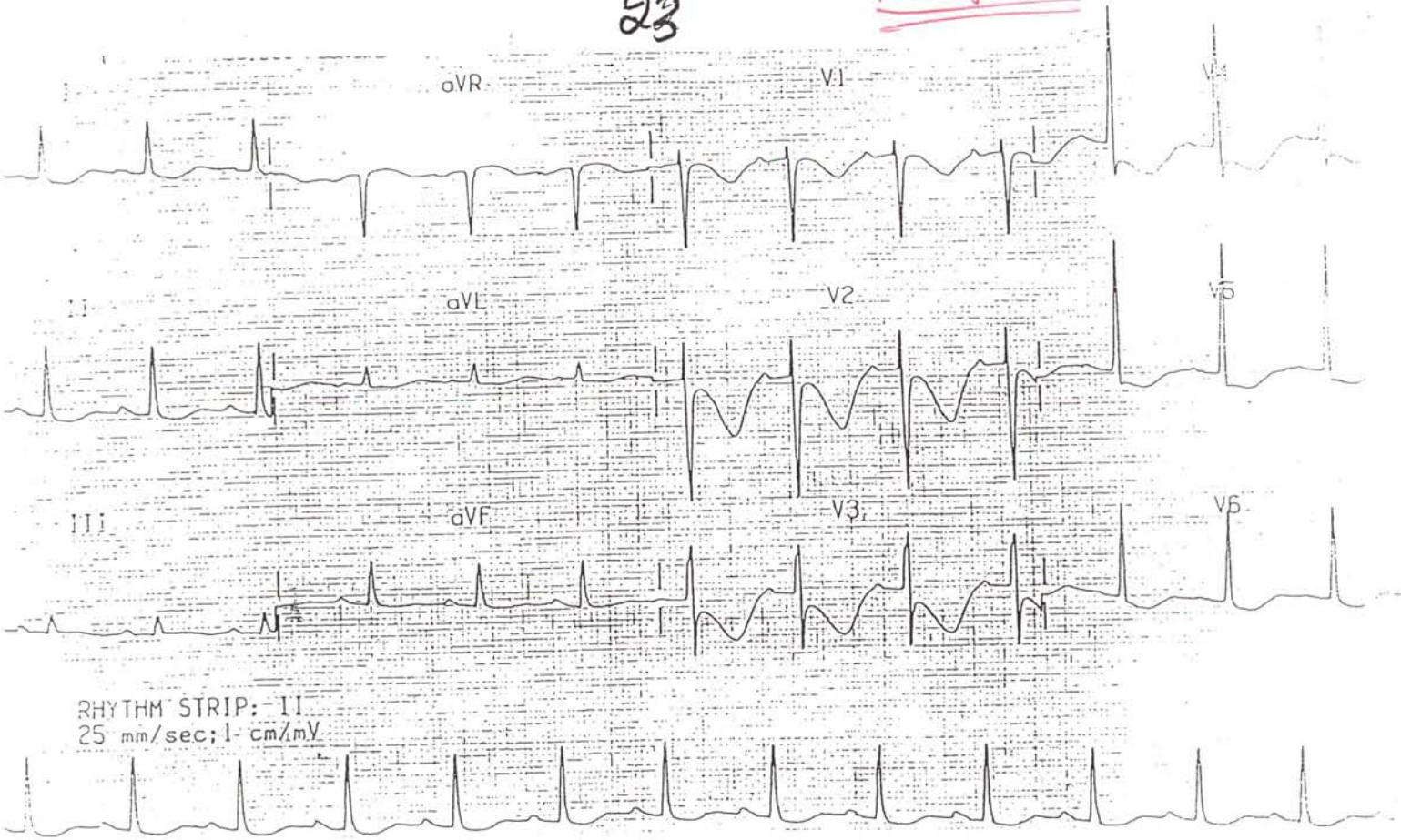
SVT



16

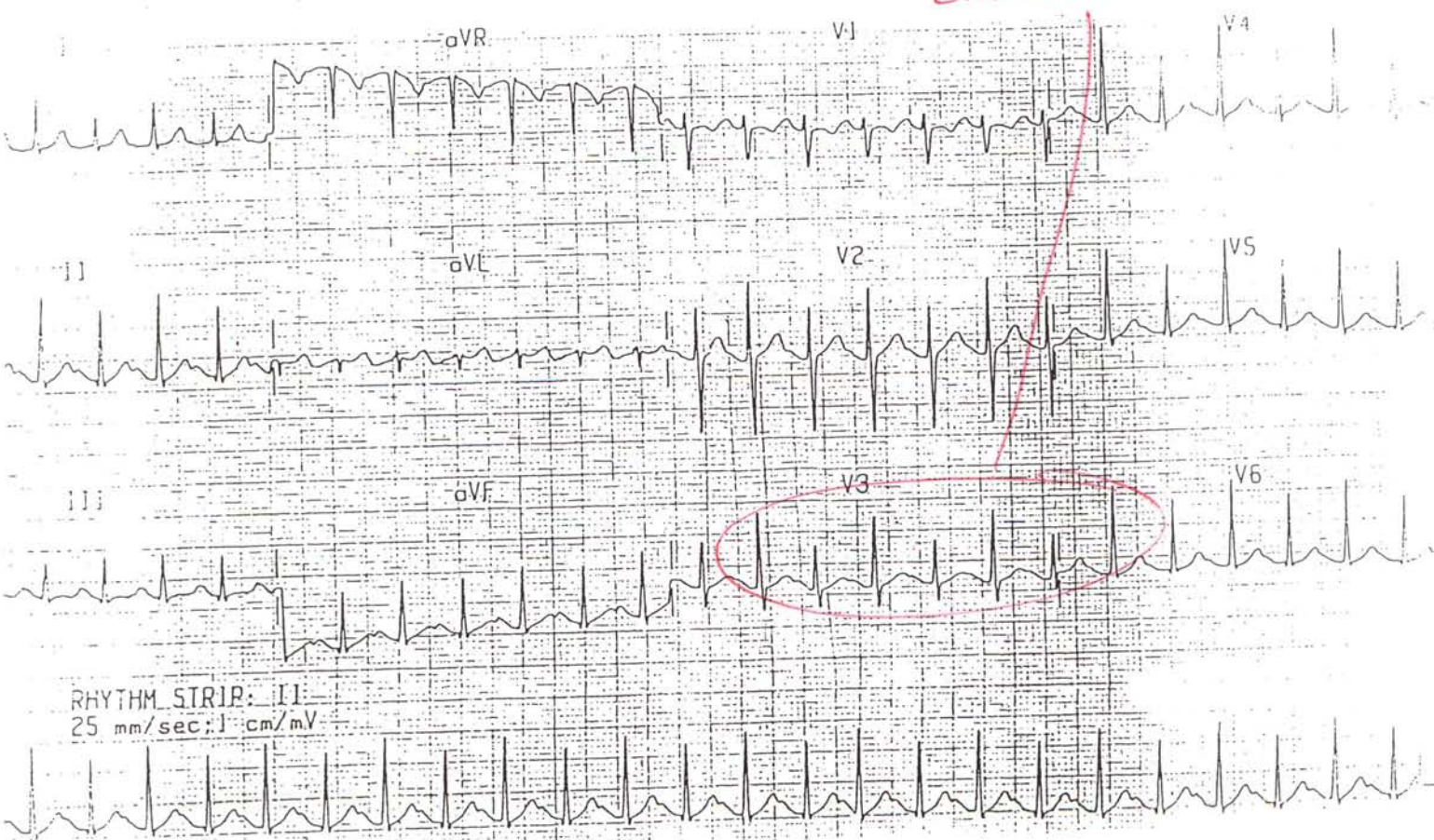
23

Prolonged QT



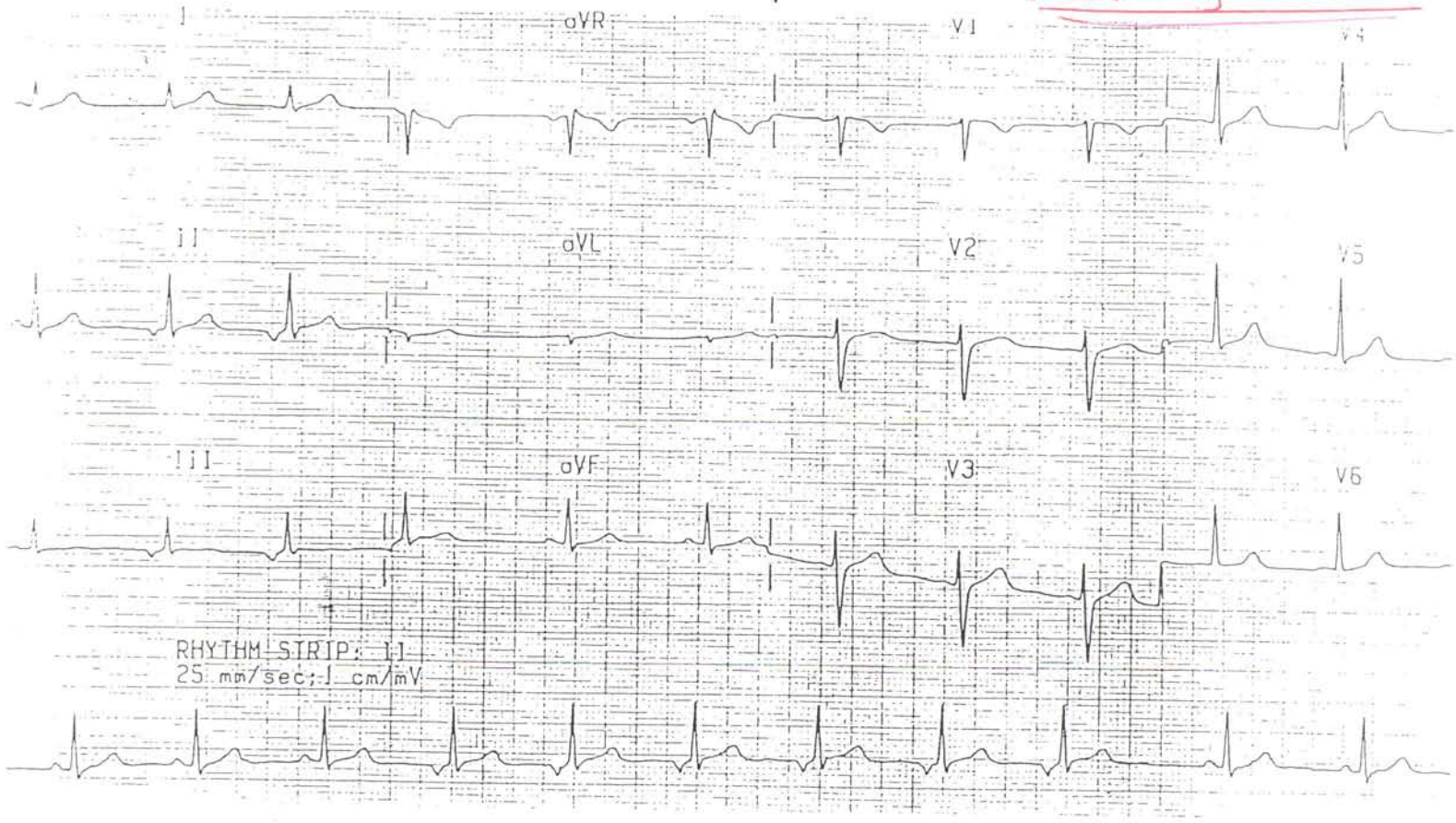
19

Electrical Alternans



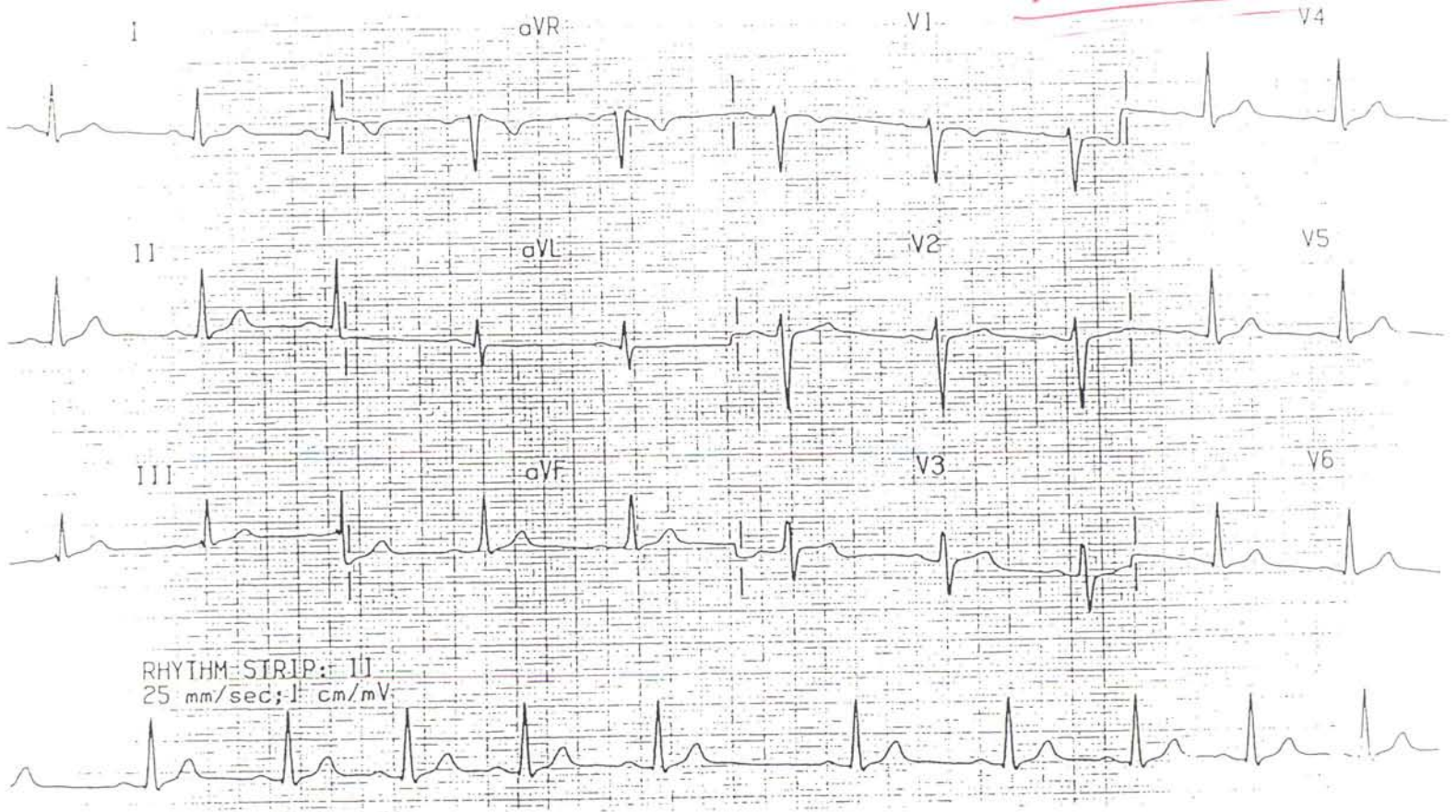
24

Wandering Pacemaker



21

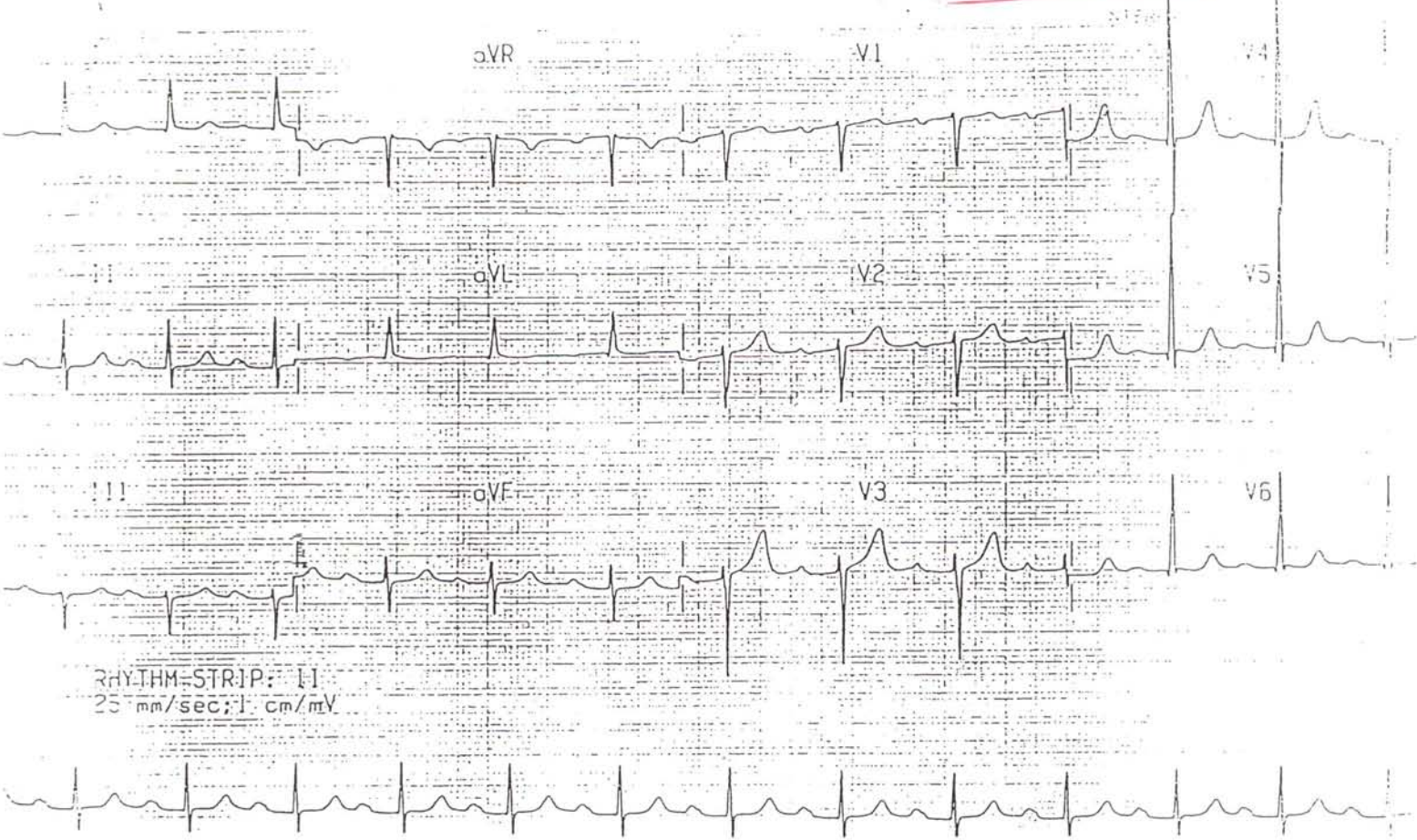
Sinus arrhythmia



22

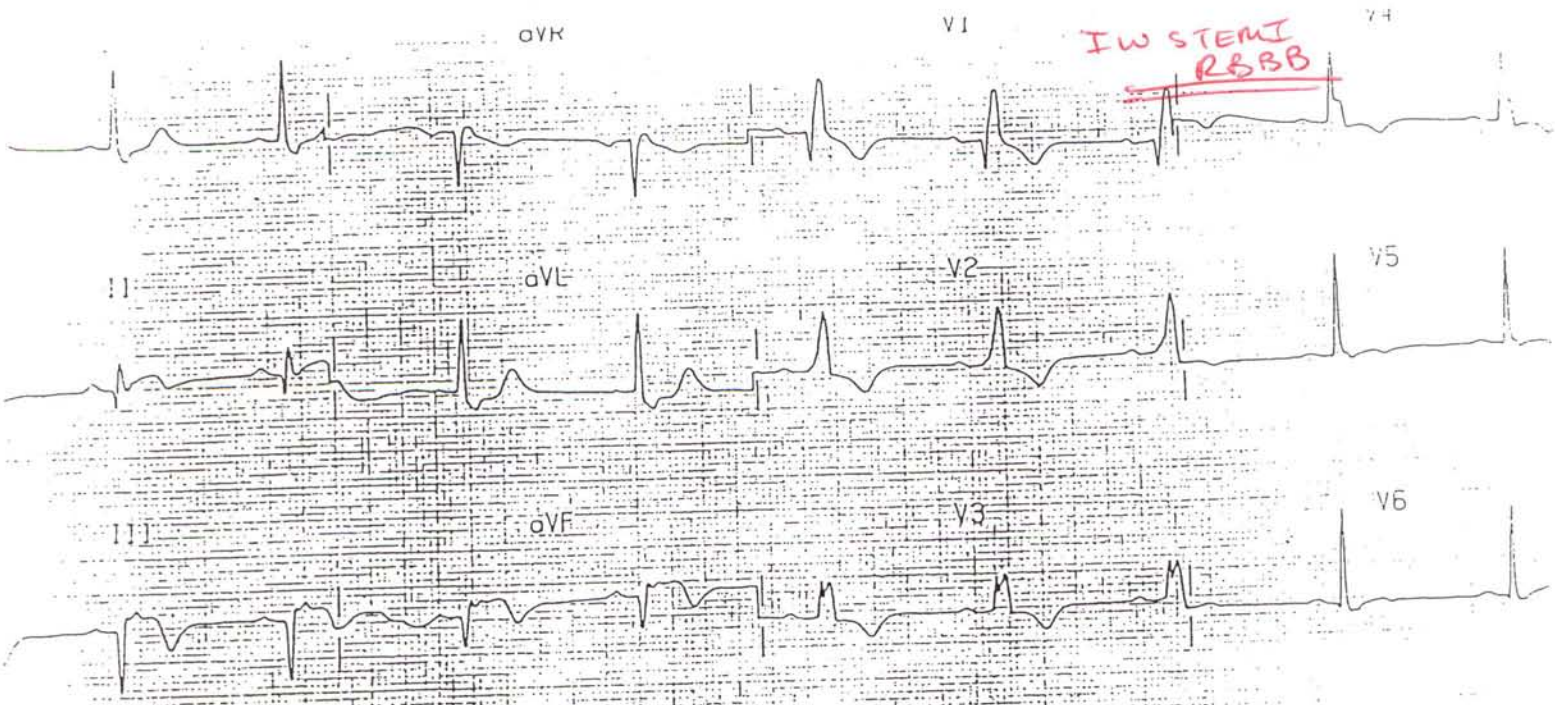
25

1st Degree AV Block



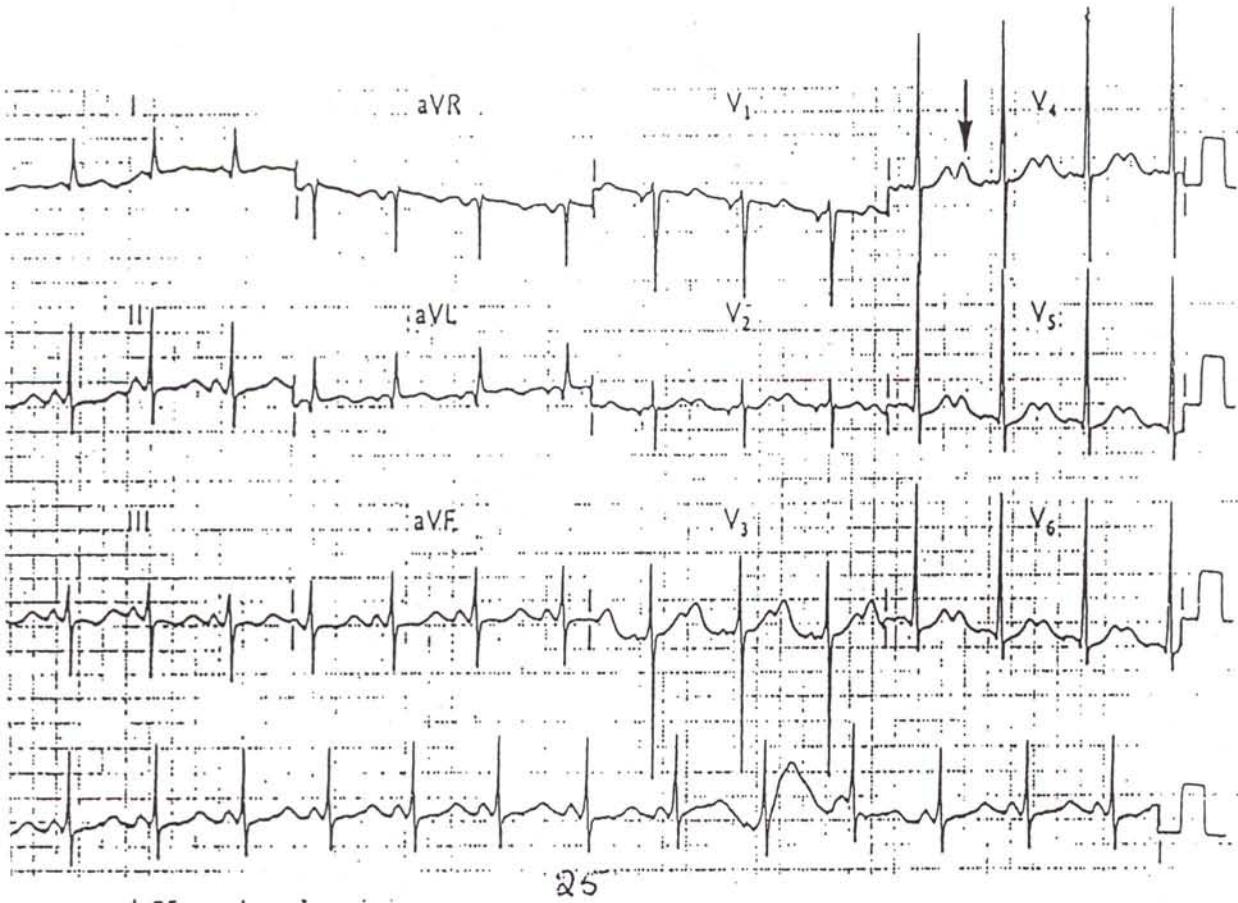
23

IW STEMI RBBB



RHYTHM-STRIP: II
25 mm/sec; 1 cm/mV

U-waves → H₂ polkaemia



Answers to Cardiology Questions

- | | | | |
|-----|---|-----|---|
| 1. | D | 26. | A |
| 2. | D | 27. | C |
| 3. | A | 28. | B |
| 4. | C | 29. | C |
| 5. | C | 30. | B |
| 6. | D | 31. | D |
| 7. | C | 32. | C |
| 8. | C | 33. | F |
| 9. | A | 34. | F |
| 10. | A | 35. | F |
| 11. | B | 36. | F |
| 12. | B | 37. | T |
| 13. | D | 38. | T |
| 14. | C | 39. | T |
| 15. | B | 40. | T |
| 16. | D | 41. | T |
| 17. | C | 42. | T |
| 18. | D | 43. | T |
| 19. | A | 44. | T |
| 20. | D | 45. | F |
| 21. | C | 46. | T |
| 22. | D | 47. | T |
| 23. | D | 48. | T |
| 24. | C | 49. | T |
| 25. | D | 50. | F |

EKG Slides

1. Junctional tachycardia
2. Multifocal atrial tachycardia
3. Mobitz type I second degree block
4. Mobitz type II second degree block
5. Inferior wall MI with AV dissociation
6. Ventricular tachycardia
7. WPW syndrome
8. RBBB, sinus bradycardia
9. Atrial flutter with 2:1 conduction
10. PAT with 2:1 conduction
11. LBBB
12. Antero-lateral MI
13. Inferior and posterior wall MI
14. Hyperkalemia, LVH
15. Pericarditis
16. Atrial fibrillation, LVH, LAHB
17. Atrial fibrillation with AV block
18. SVT
19. Prolonged QT interval
20. Cardiac tamponade
21. Wandering atrial pacemaker
22. Sinus arrhythmia and sinus arrest
23. First-Degree AV block
24. Inferior wall MI with RBBB
25. Hypokalemia